

# 教育セミナー（診断編）

第19回日本乳癌学会中部地方会



**The Japanese Breast Cancer Society**  
since 1992

筆頭演者の利益相反状態の開示

すべての項目に該当なし

## 出題内容

### Q1. 検診MG

所見・推定疾患・カテゴリー

### Q2. トモシンセシス

腫瘍なのかFADなのか、病変はどの範囲まであると思うか

### Q3. US(精査)

所見・推定疾患・浸潤の有無・カテゴリー

### Q4. MRI

ご施設ではどんなシリーズをどんな手順で見ているか

症例 70代後半 女性

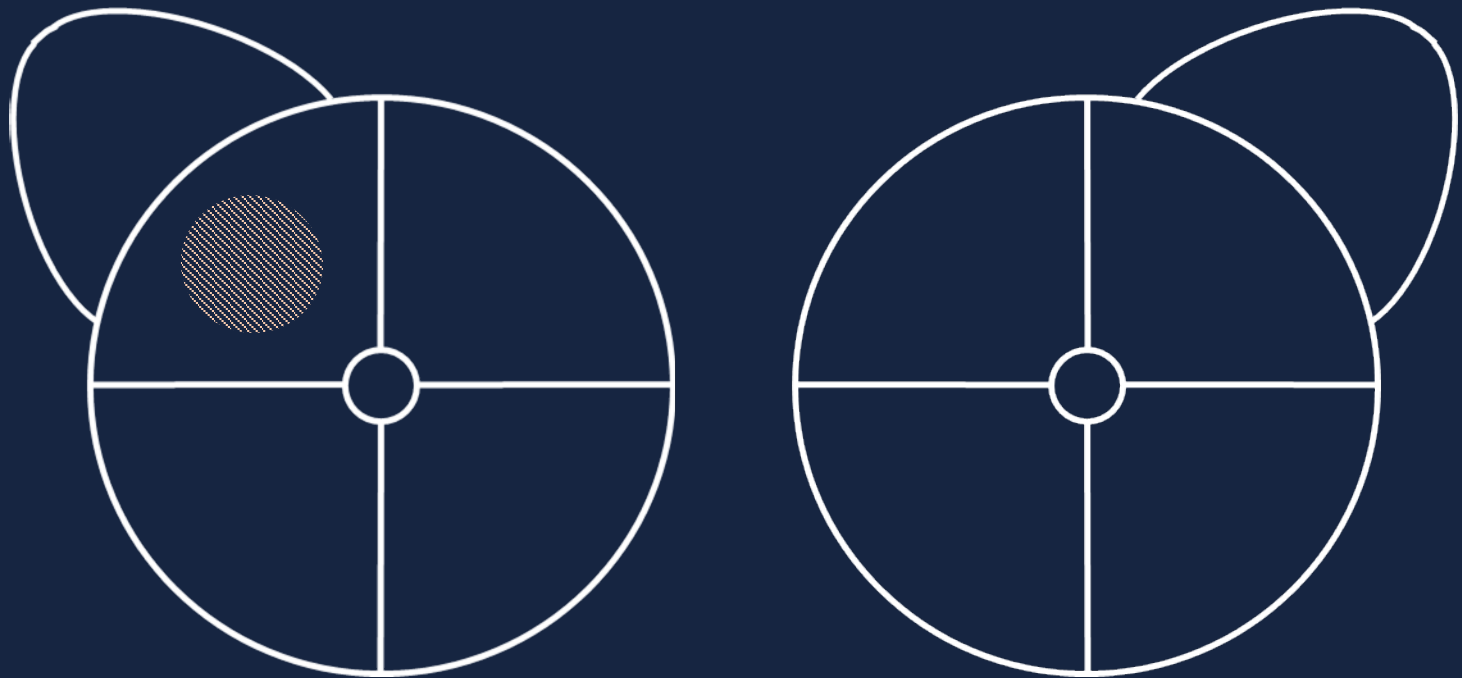
主訴: MG・US併用検診で要精検

既往歴: 心肥大、高血圧

家族歴: 妹が乳癌(他病死)、卵巣癌なし

検診歴: 6年前 MG 異常なし  
8年前 MG 異常なし  
9年前 US 精査不要(右Aに小嚢胞)





視触診： 右Cに硬結を認める。(但し無自覚)

## 出題内容

### Q1. 検診MG

所見・推定疾患・カテゴリー

### Q2. トモシンセシス

腫瘍なのかFADなのか、病変はどの範囲まであると思うか

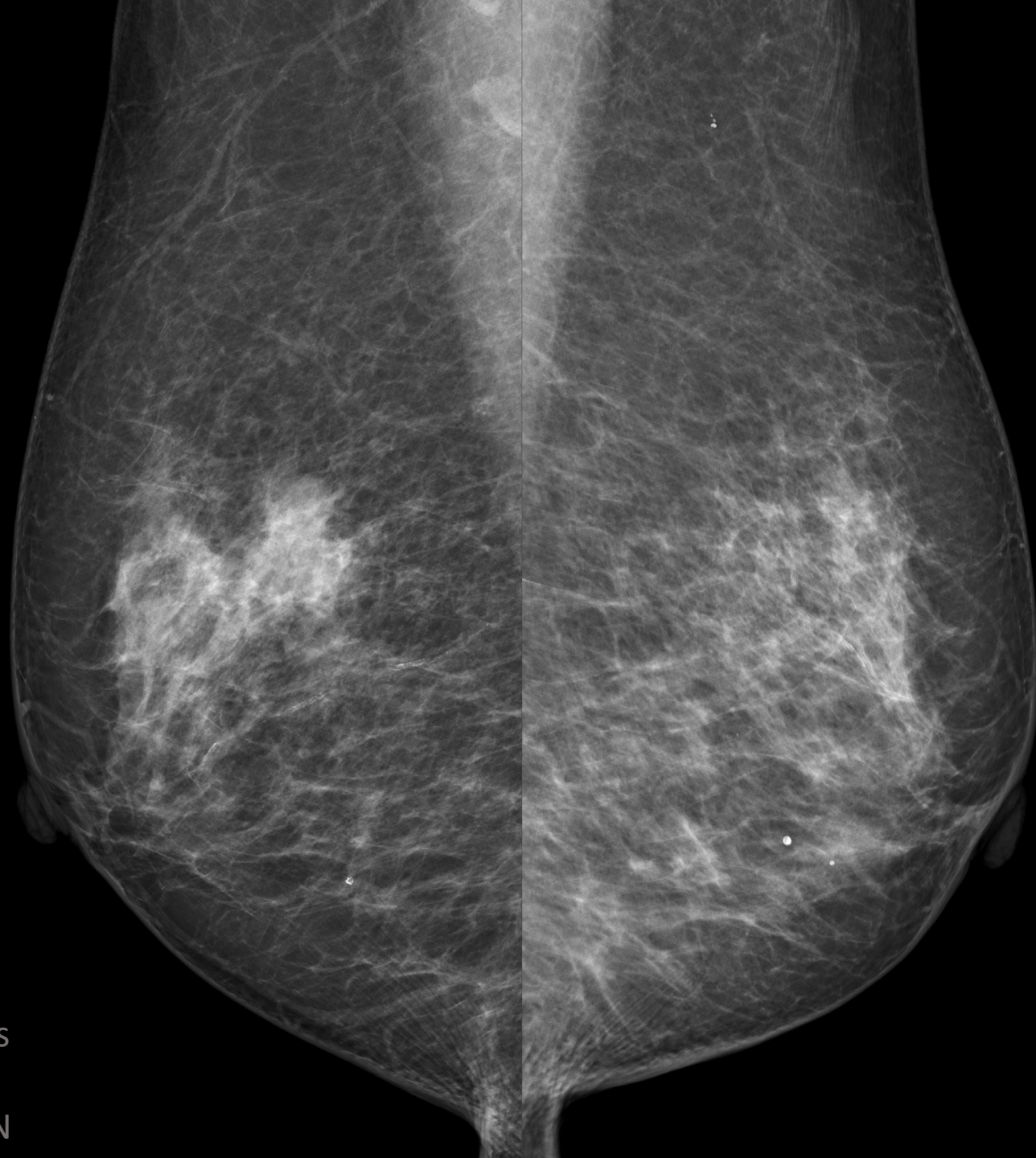
### Q3. US(精査)

所見・推定疾患・浸潤の有無・カテゴリー

### Q4. MRI

ご施設ではどんなシリーズをどんな手順で見ているか

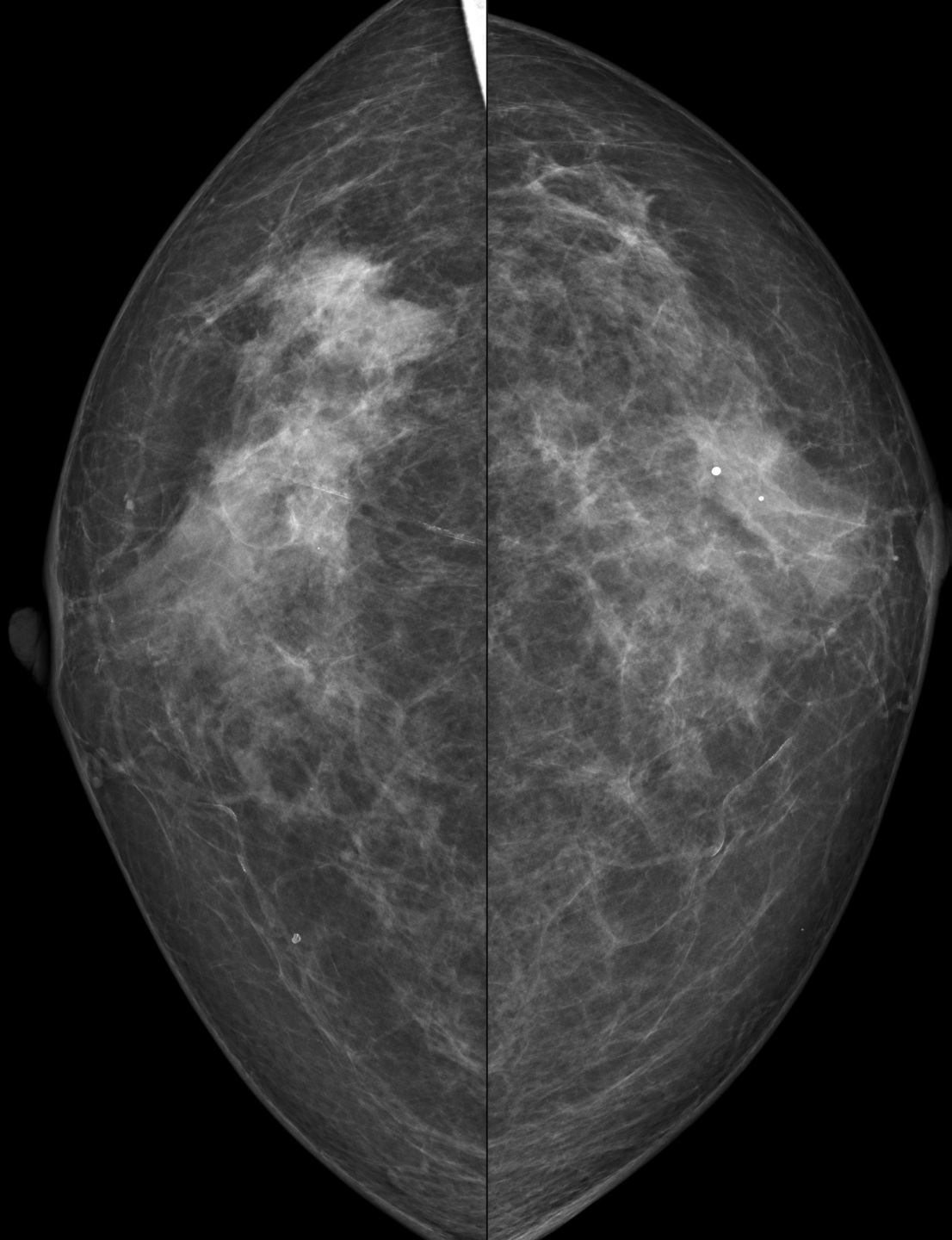
今回



Mo/Mo  
27kV, 46mAs  
1.55mGy  
29mm, 114N

Mo/Mo  
27kV, 42mAs  
1.46mGy  
28mm, 116N

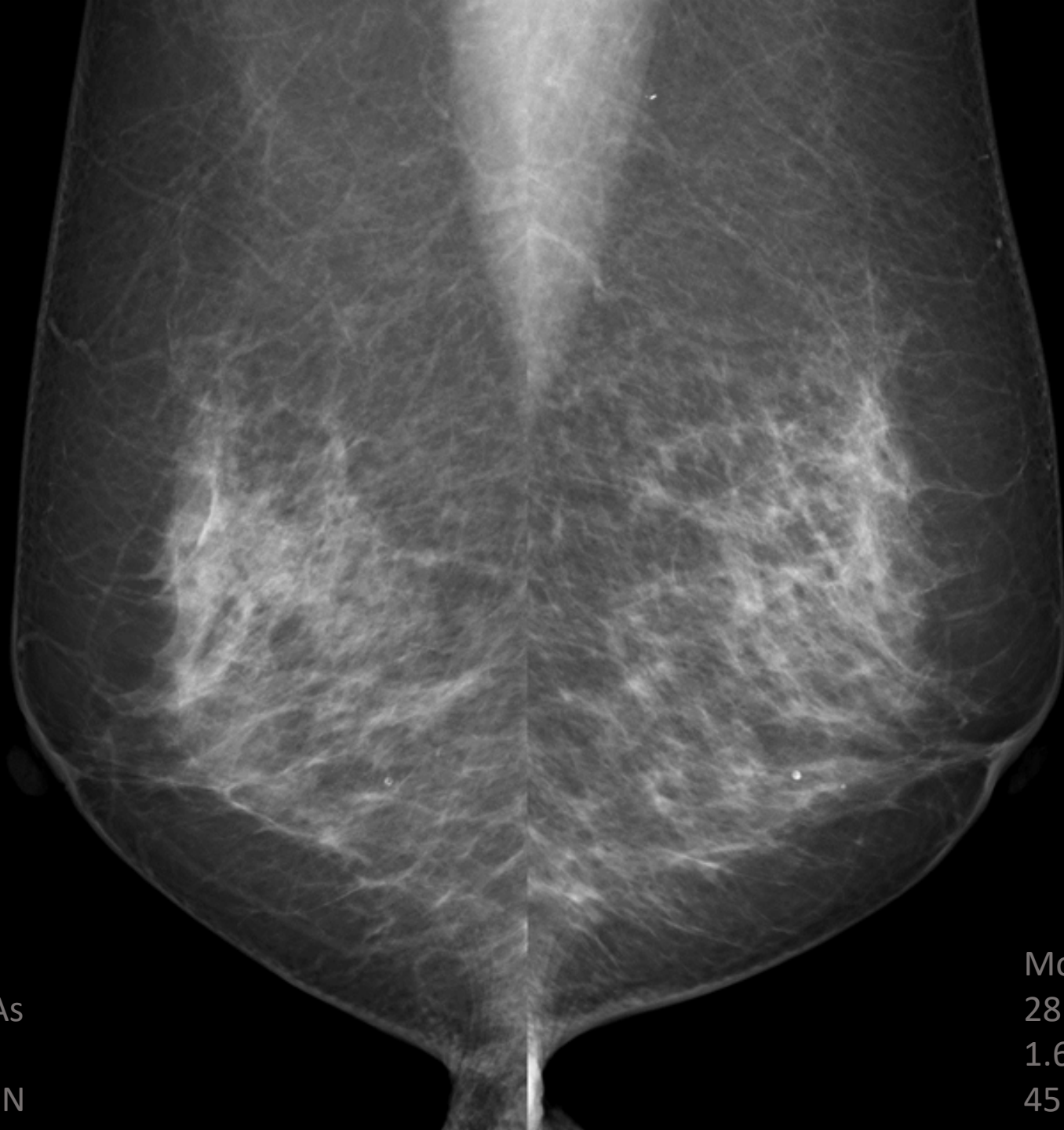今回



Mo/Mo  
27kV, 39mAs  
1.54mGy  
23mm, 120N

Mo/Mo  
26kV, 44mAs  
1.60mGy  
20mm, 120N

6年前

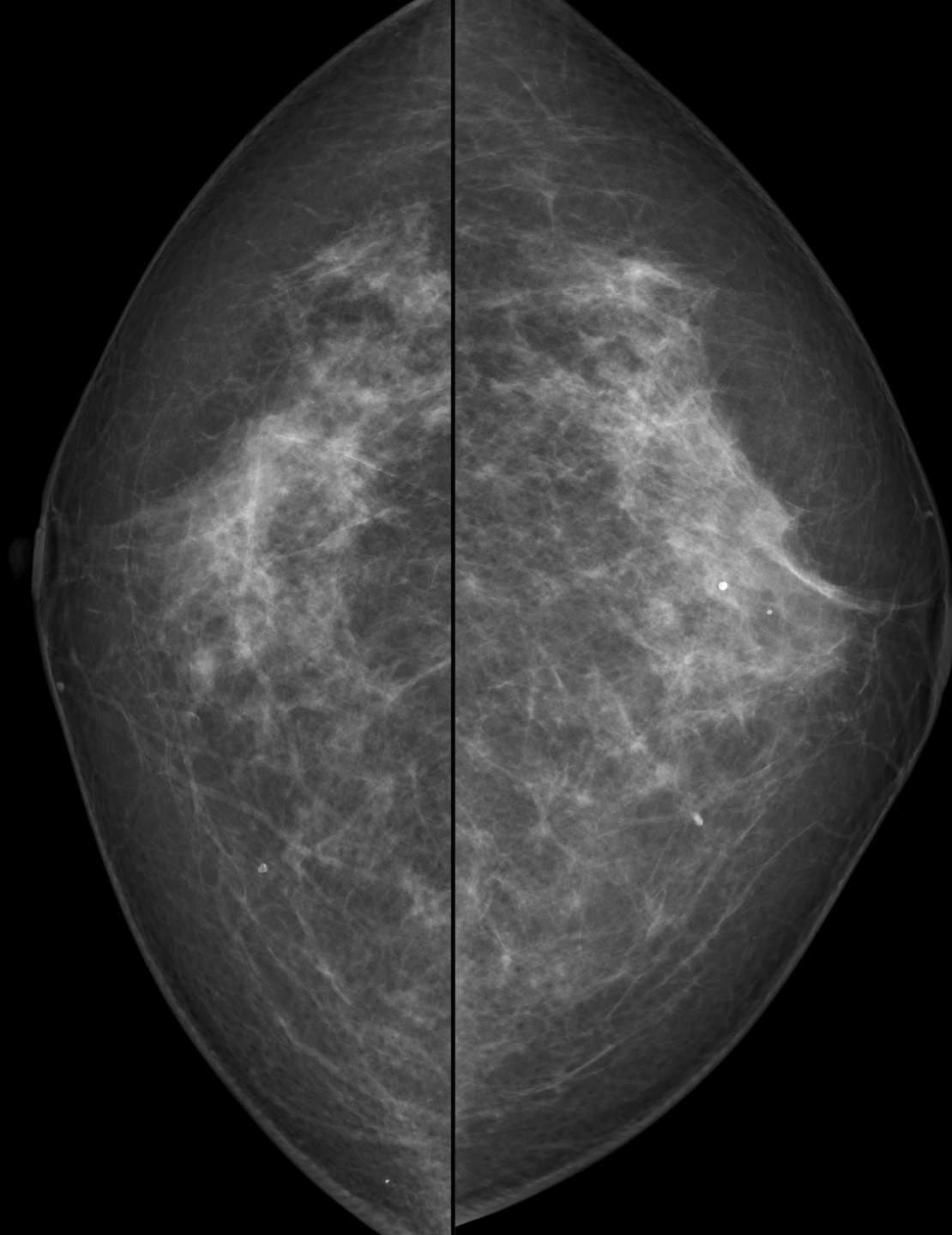


Mo/Rh  
28kV, 65mAs  
1.65mGy  
48mm, 133N

Mo/Rh  
28kV, 61mAs  
1.60mGy  
45mm, 136N



6年前



Mo/Rh  
28kV, 60mAs  
1.63mGy  
42mm, 135N

Mo/Rh  
28kV, 61mAs  
1.66mGy  
42mm, 130N

## 出題内容

### Q1. 検診MG

所見・推定疾患・カテゴリー

### Q2. トモシンセシス

腫瘍なのかFADなのか、病変はどの範囲まであると思うか

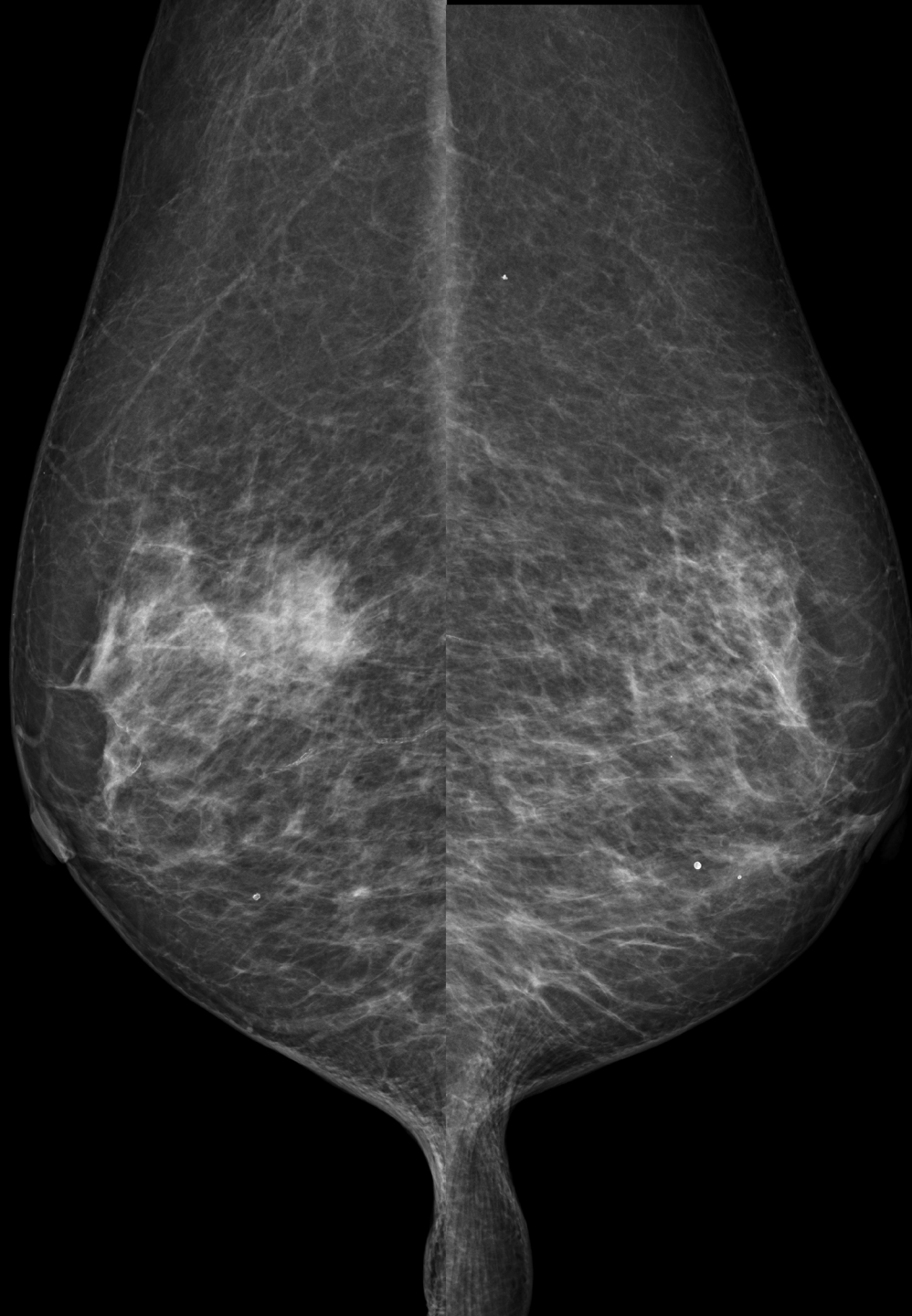
### Q3. US(精査)

所見・推定疾患・浸潤の有無・カテゴリー

### Q4. MRI

ご施設ではどんなシリーズをどんな手順で見ているか

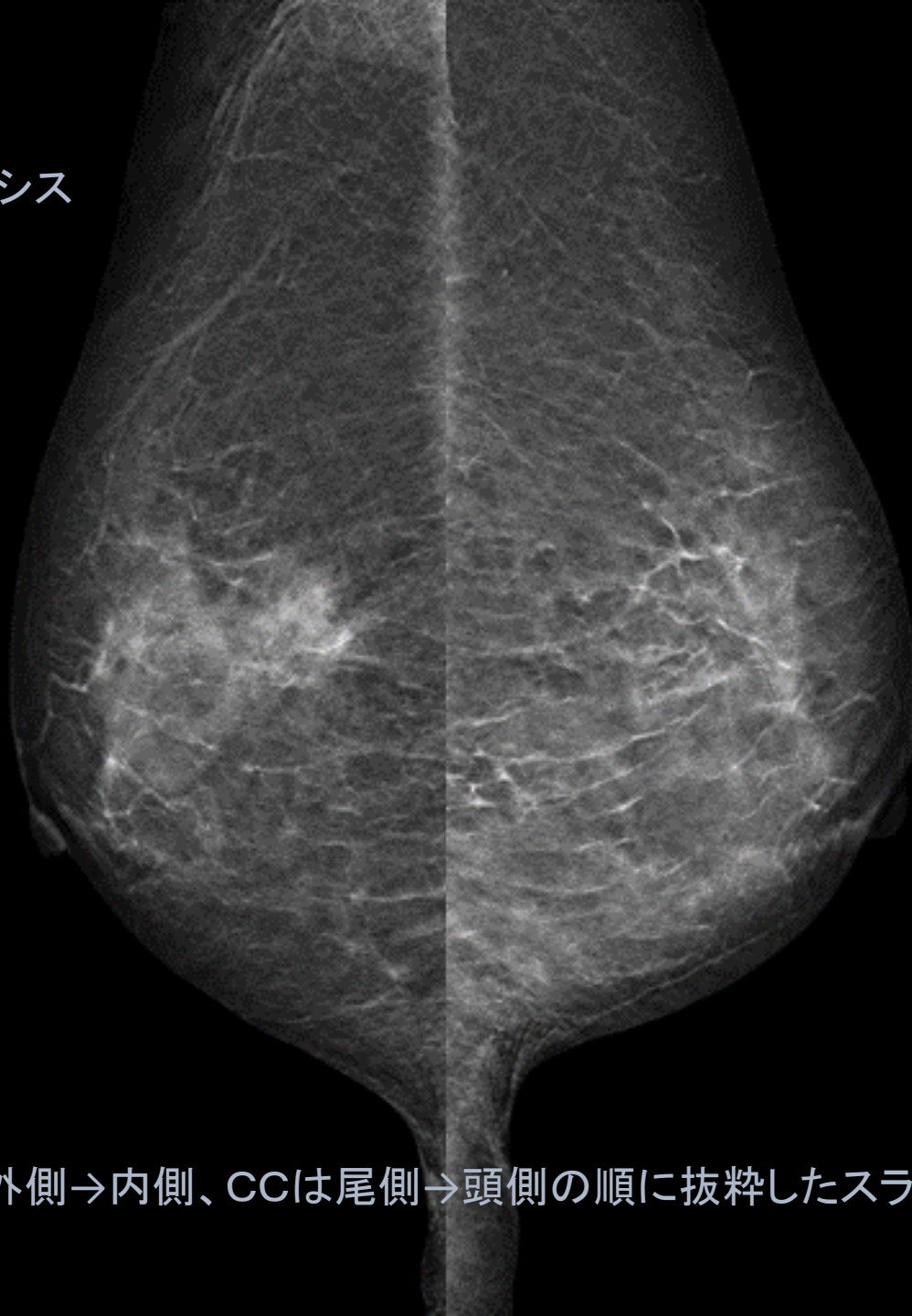
2D MG







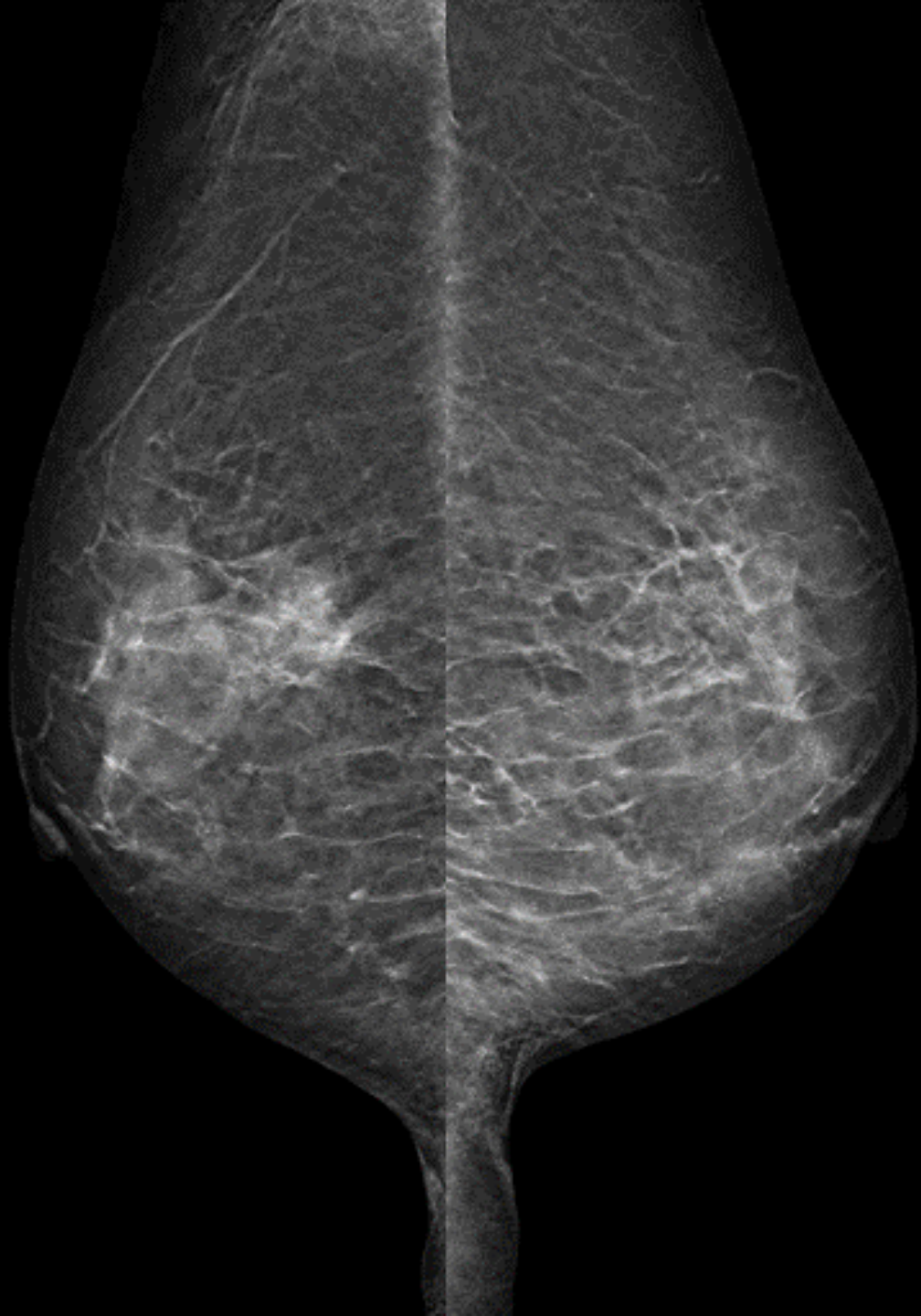
トモシンセシス



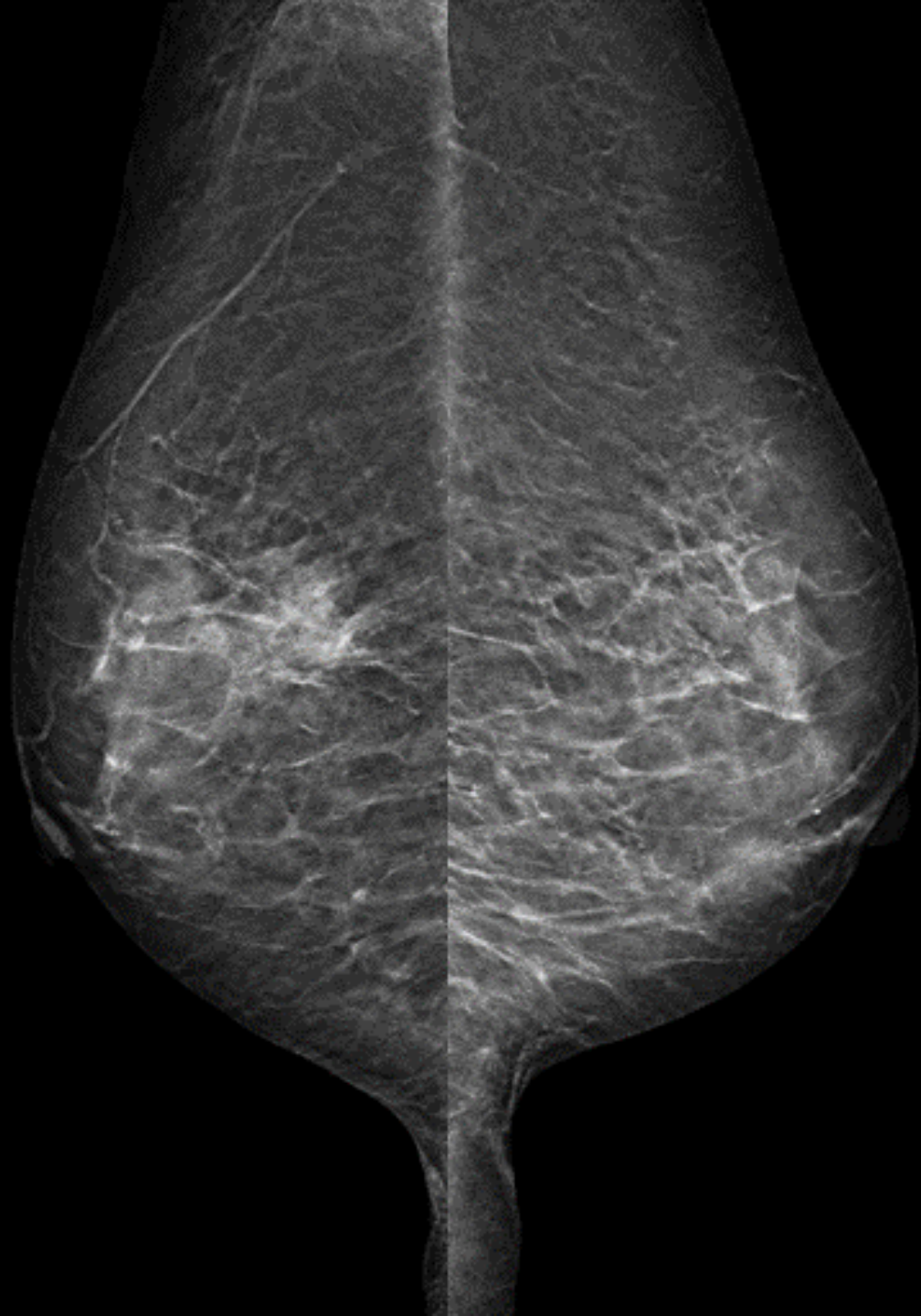
MLOは外側→内側、CCは尾側→頭側の順に抜粋したスライスを表示

R MLO

L MLO



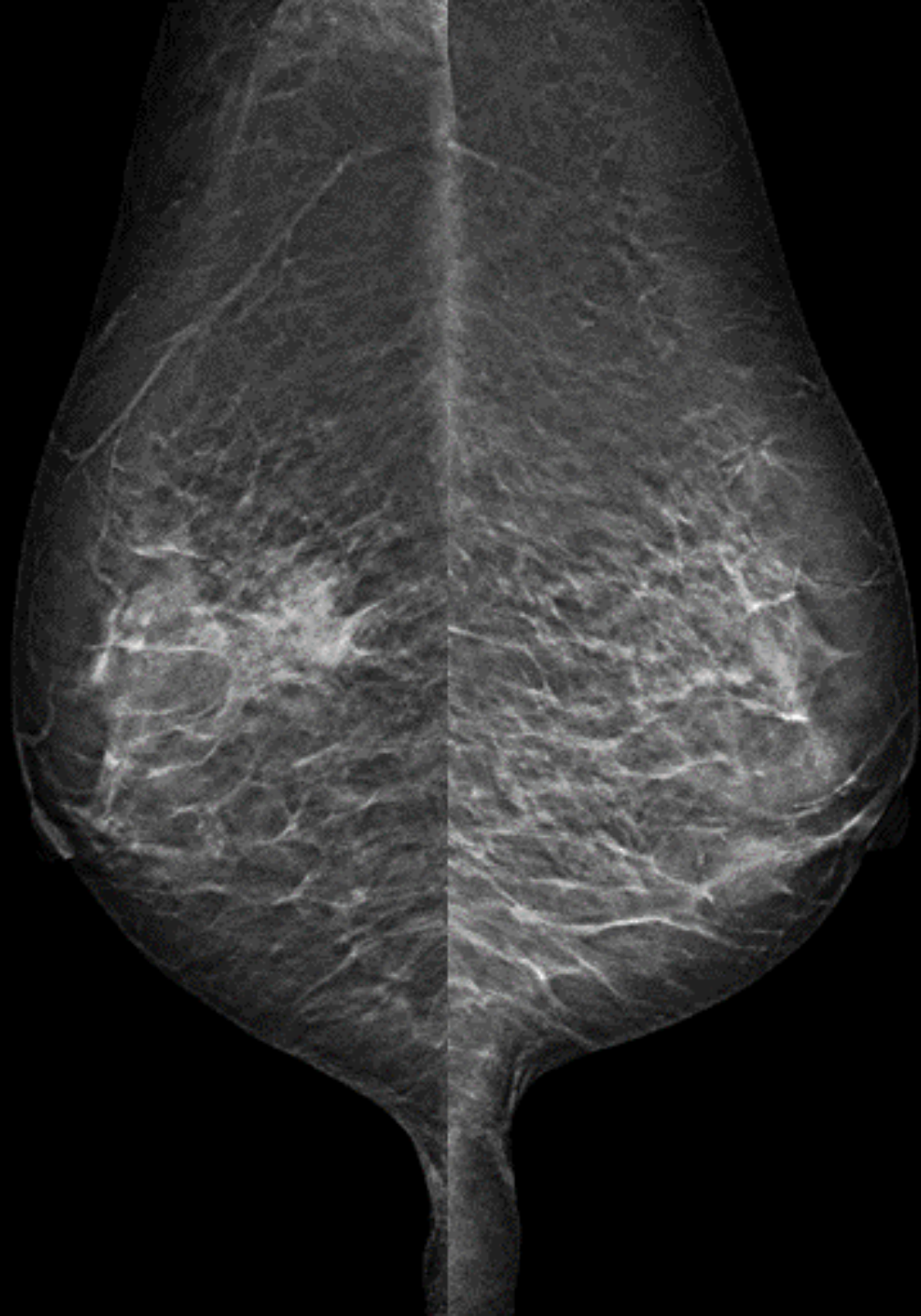
R MLO



L MLO

R MLO

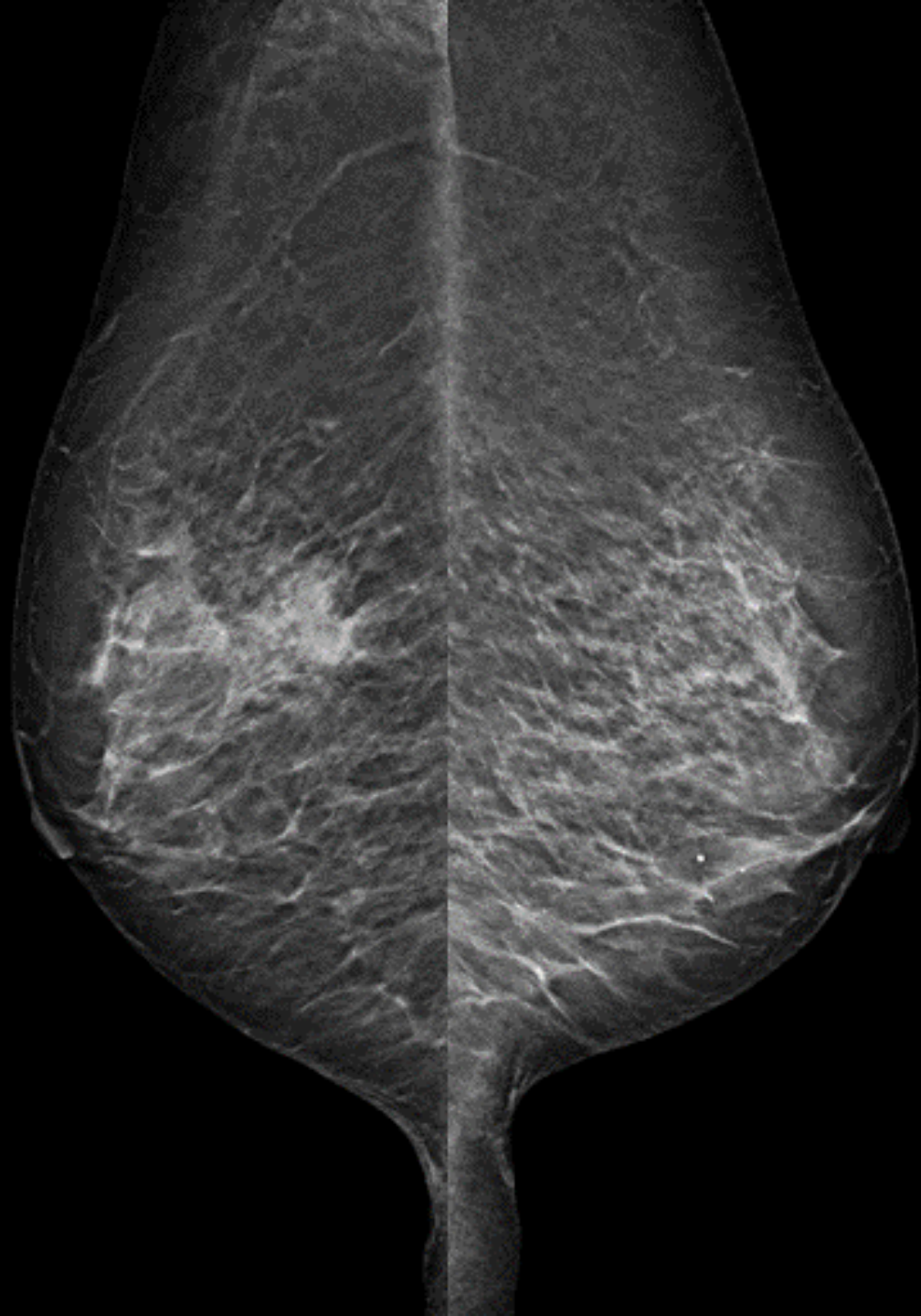
L MLO



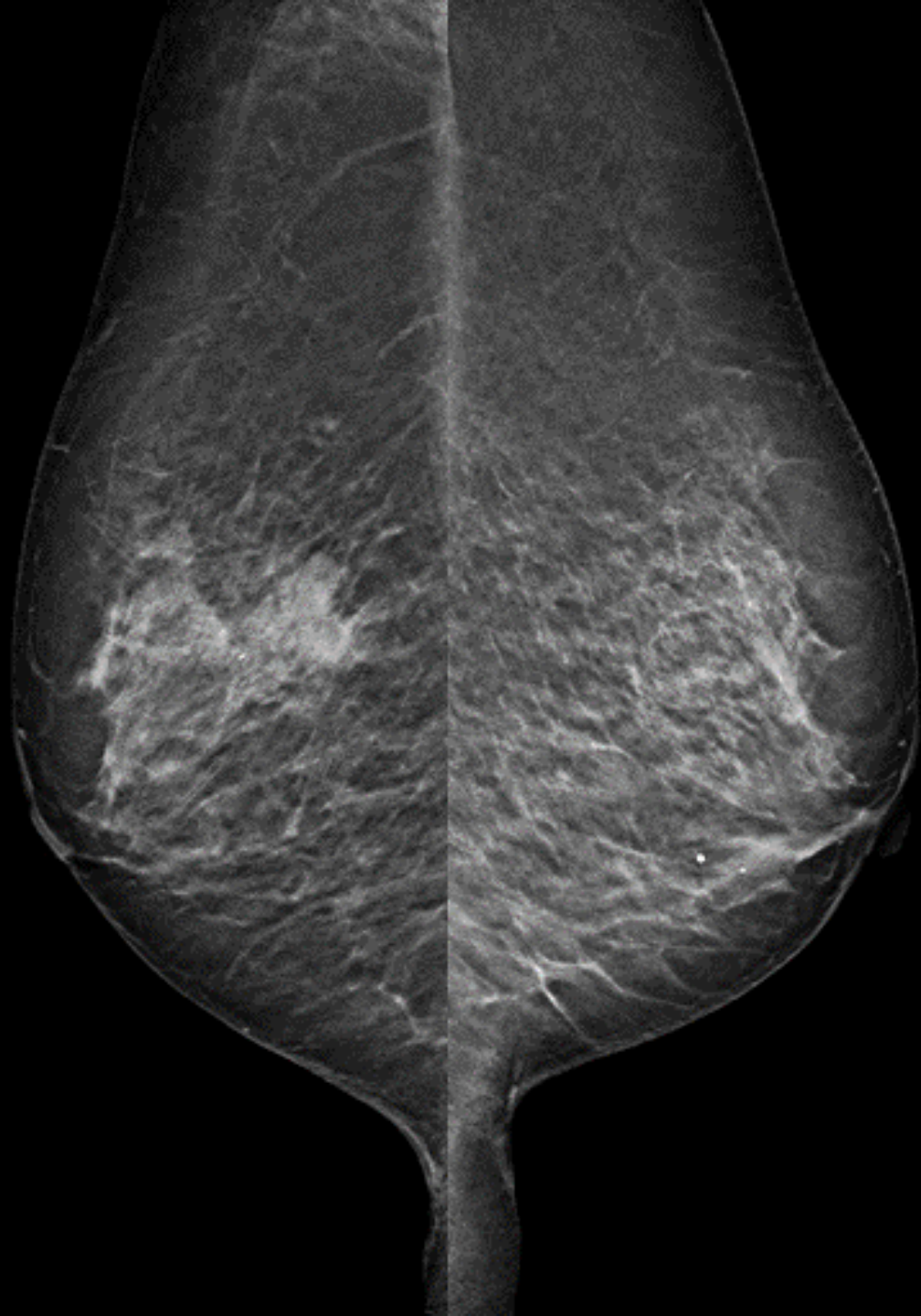

R MLO

L MLO

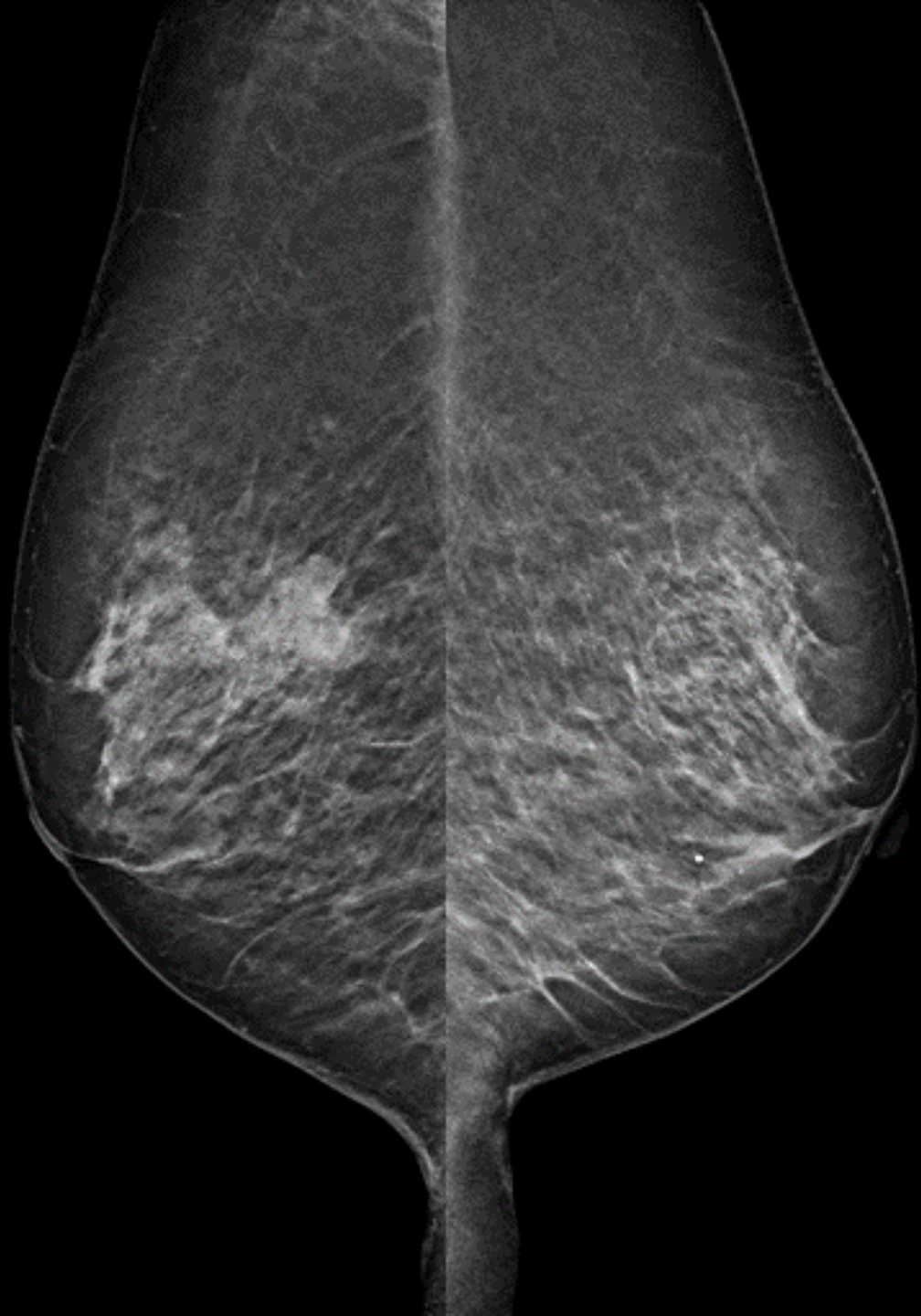


R MLO



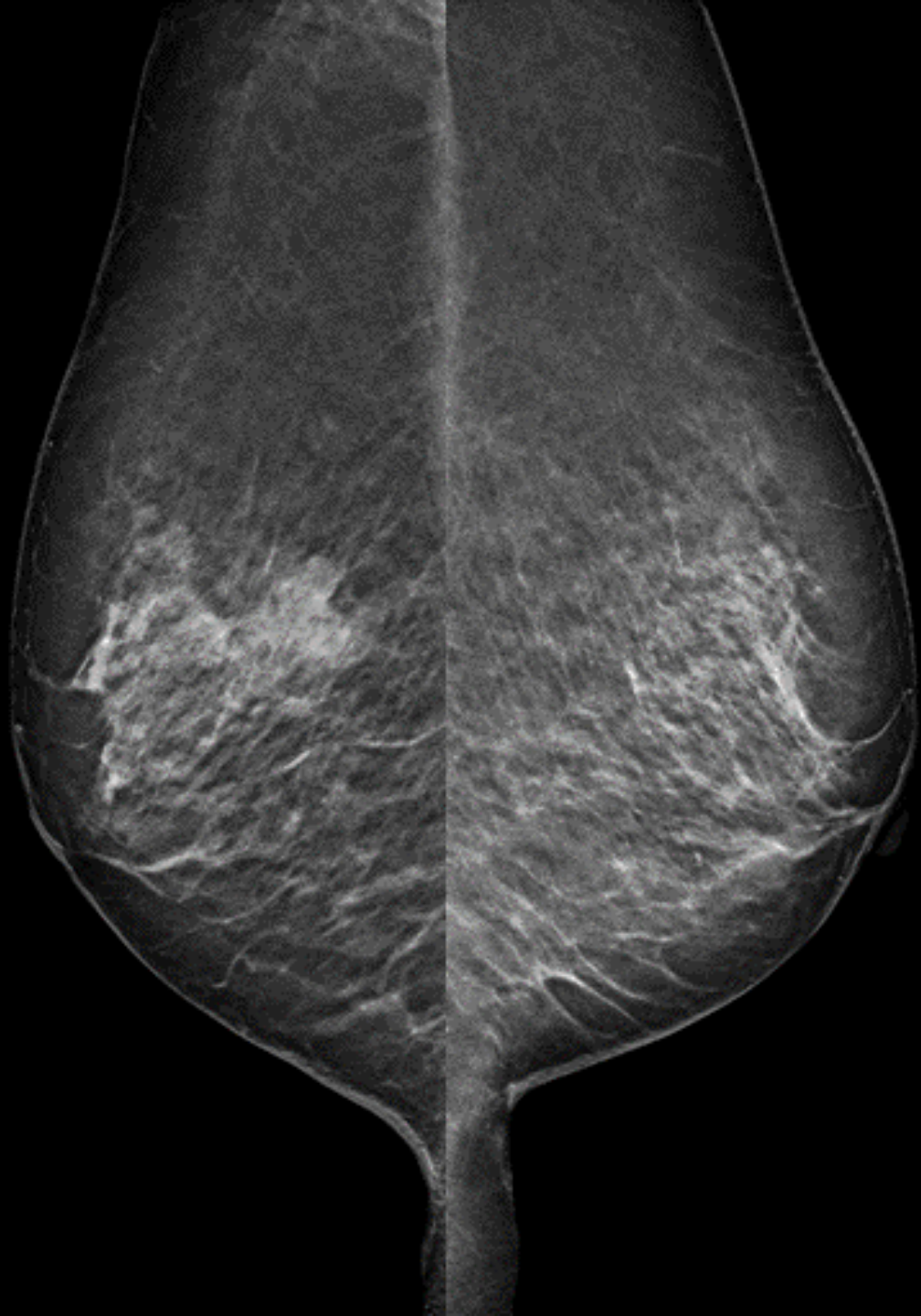L MLO

R MLO



L MLO

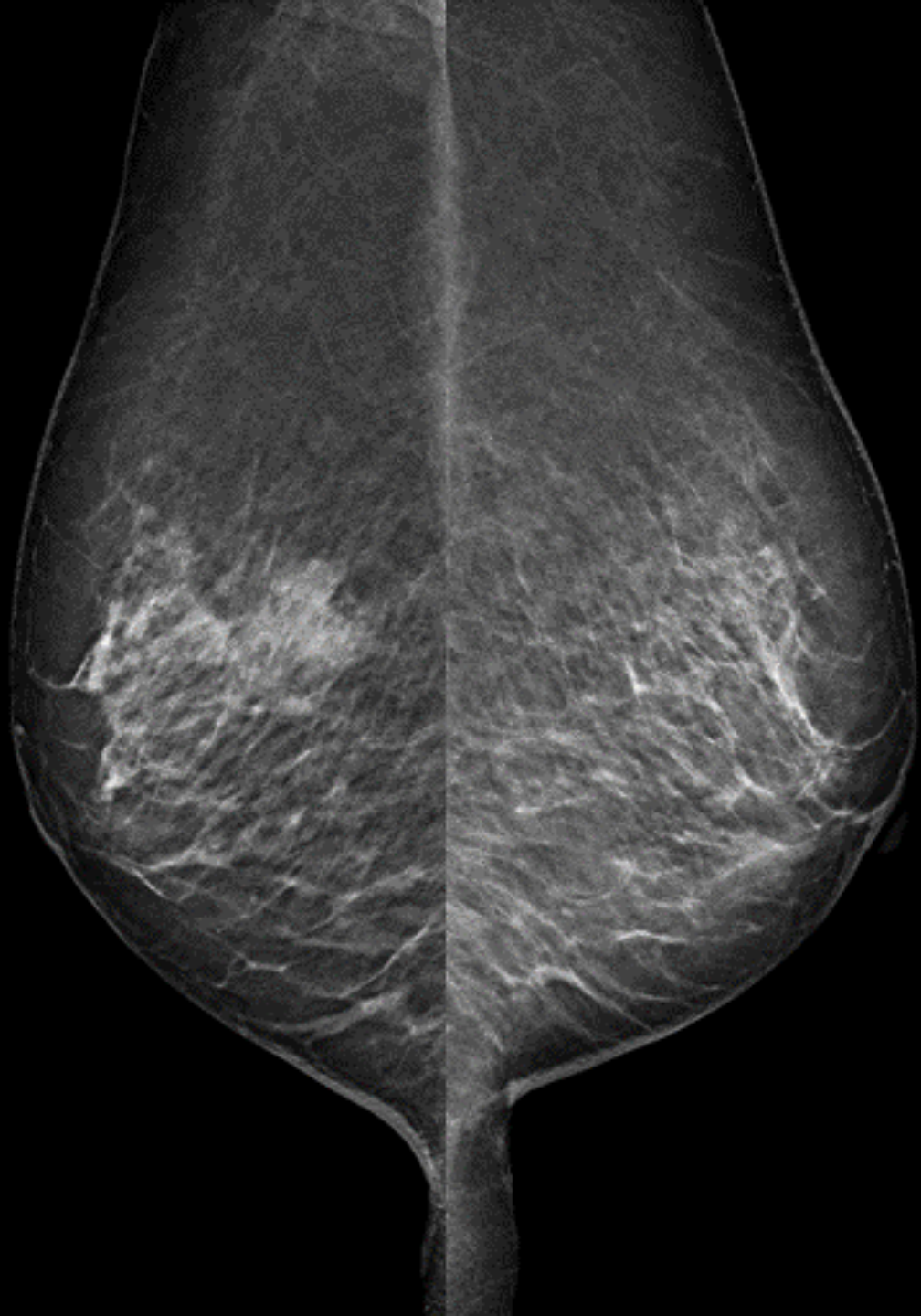R MLO



L MLO

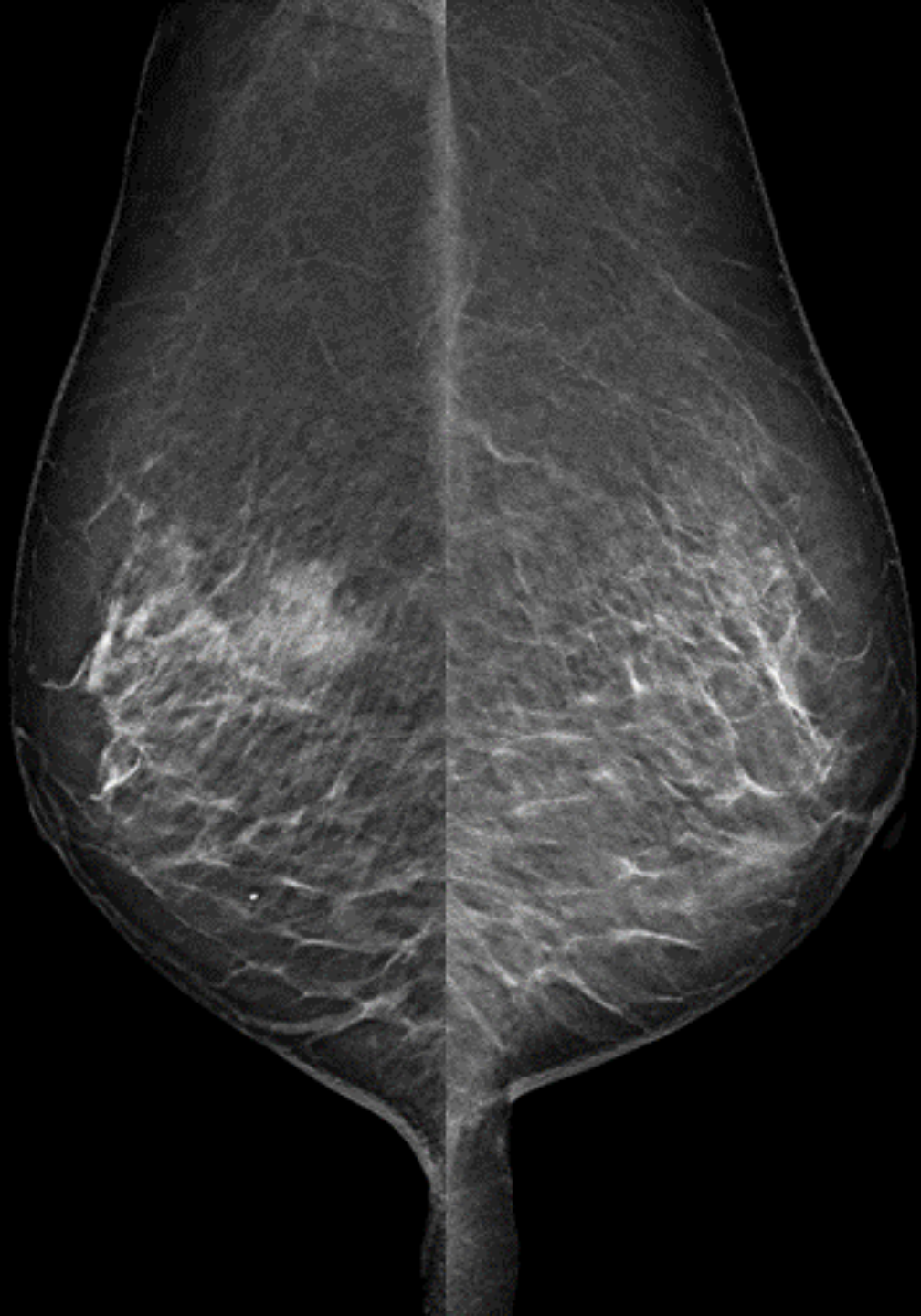

R MLO



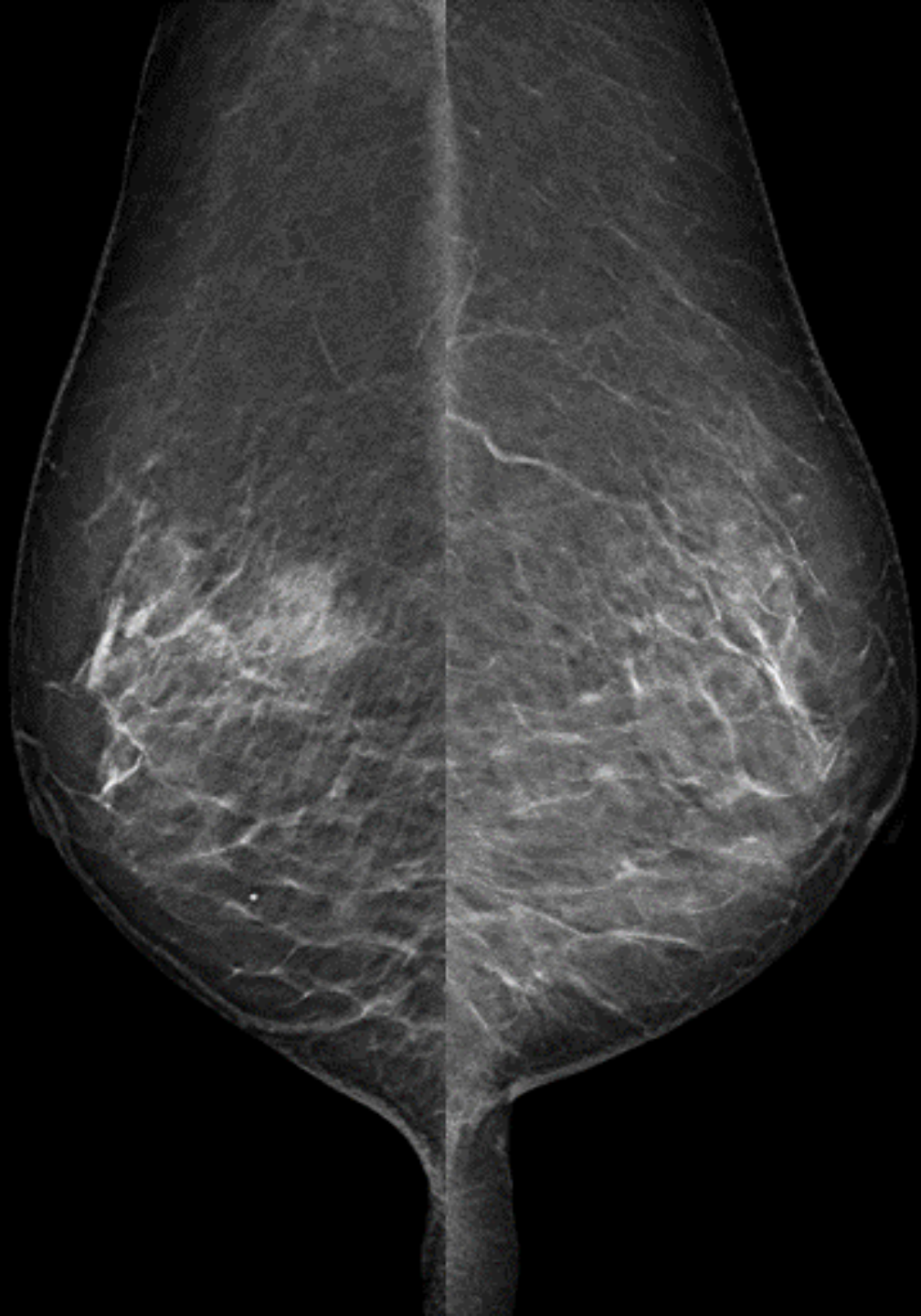
L MLO

R MLO



L MLO

R MLO

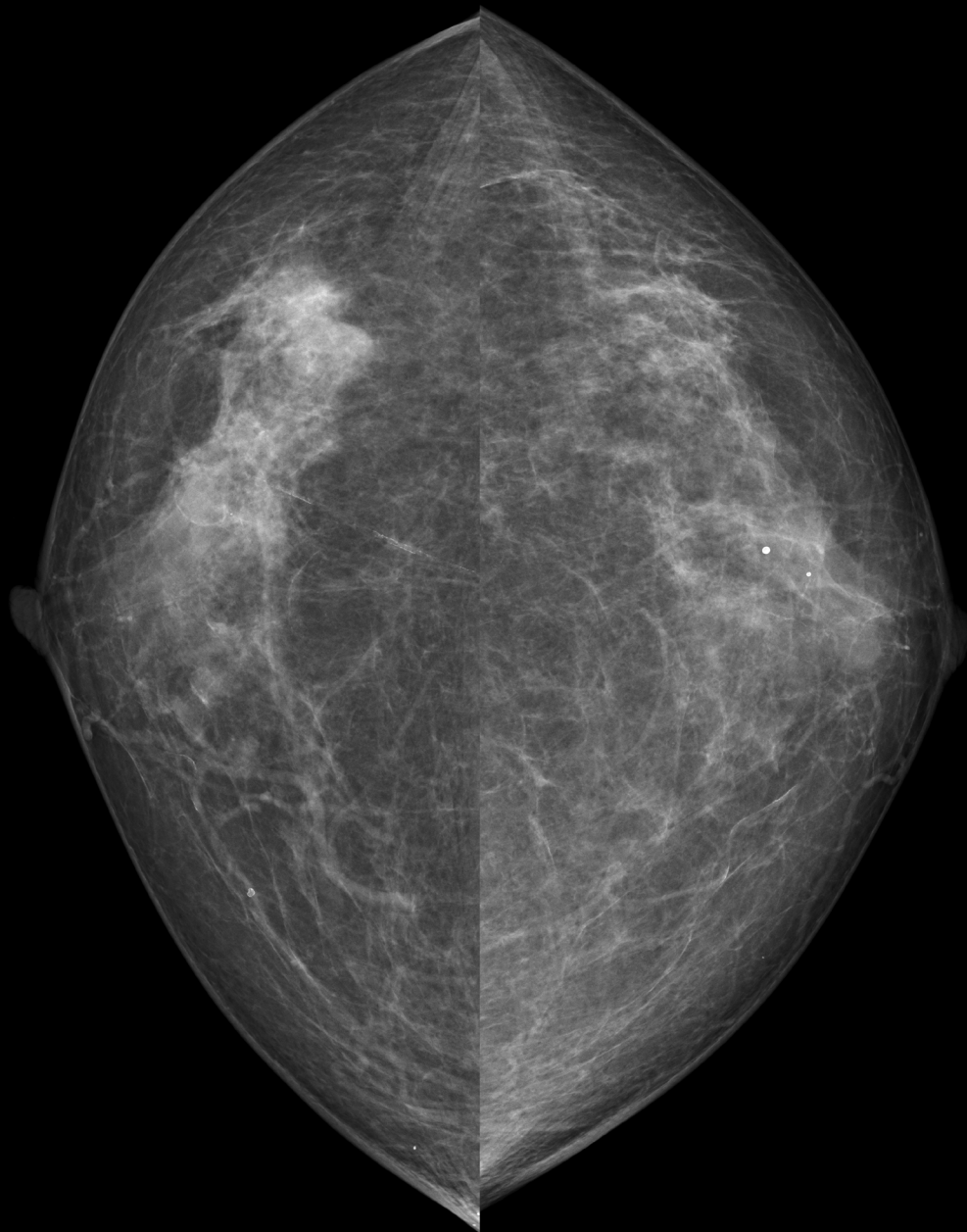


L MLO

R cc

2D MG

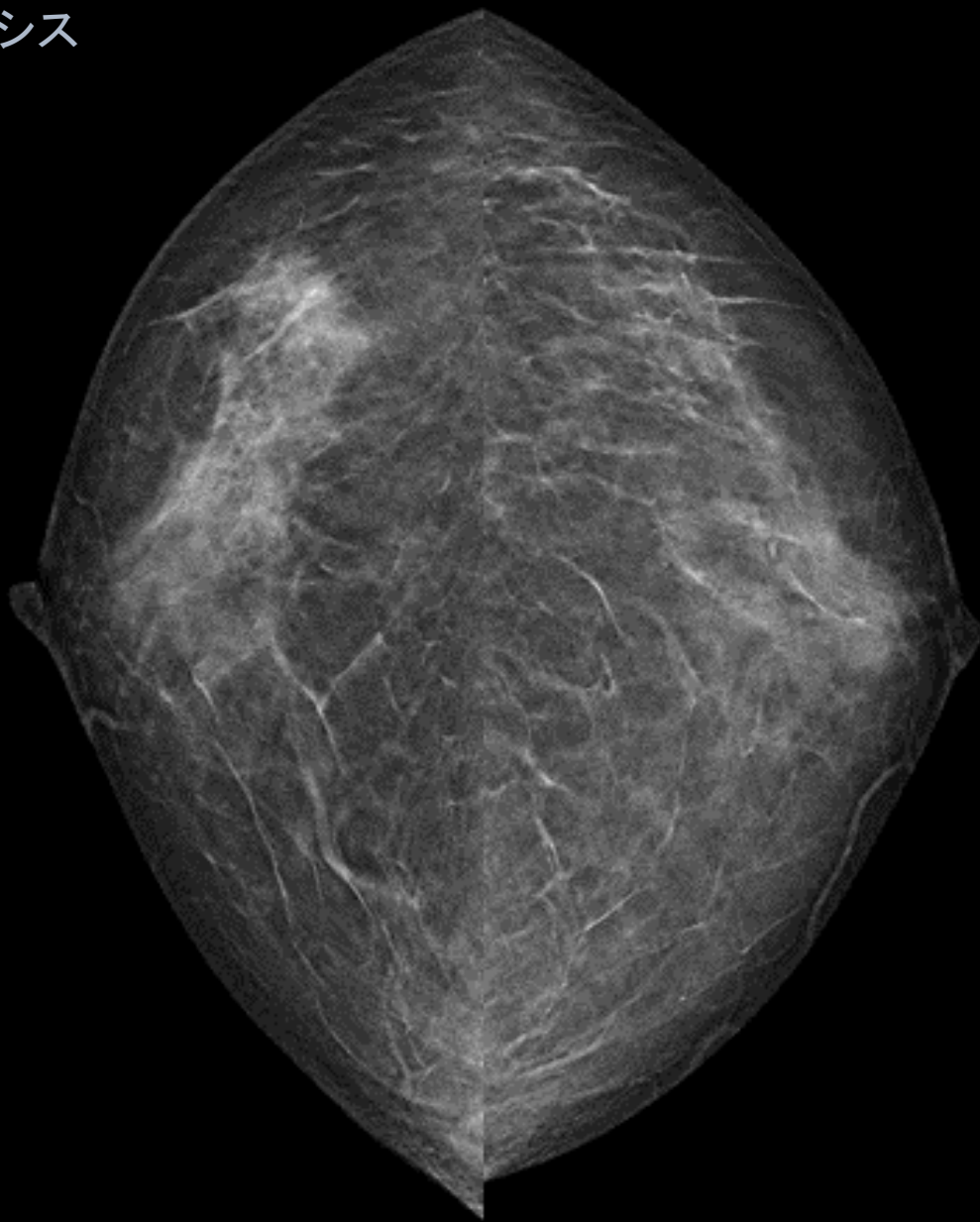
L cc



R cc <

トモシンセシス

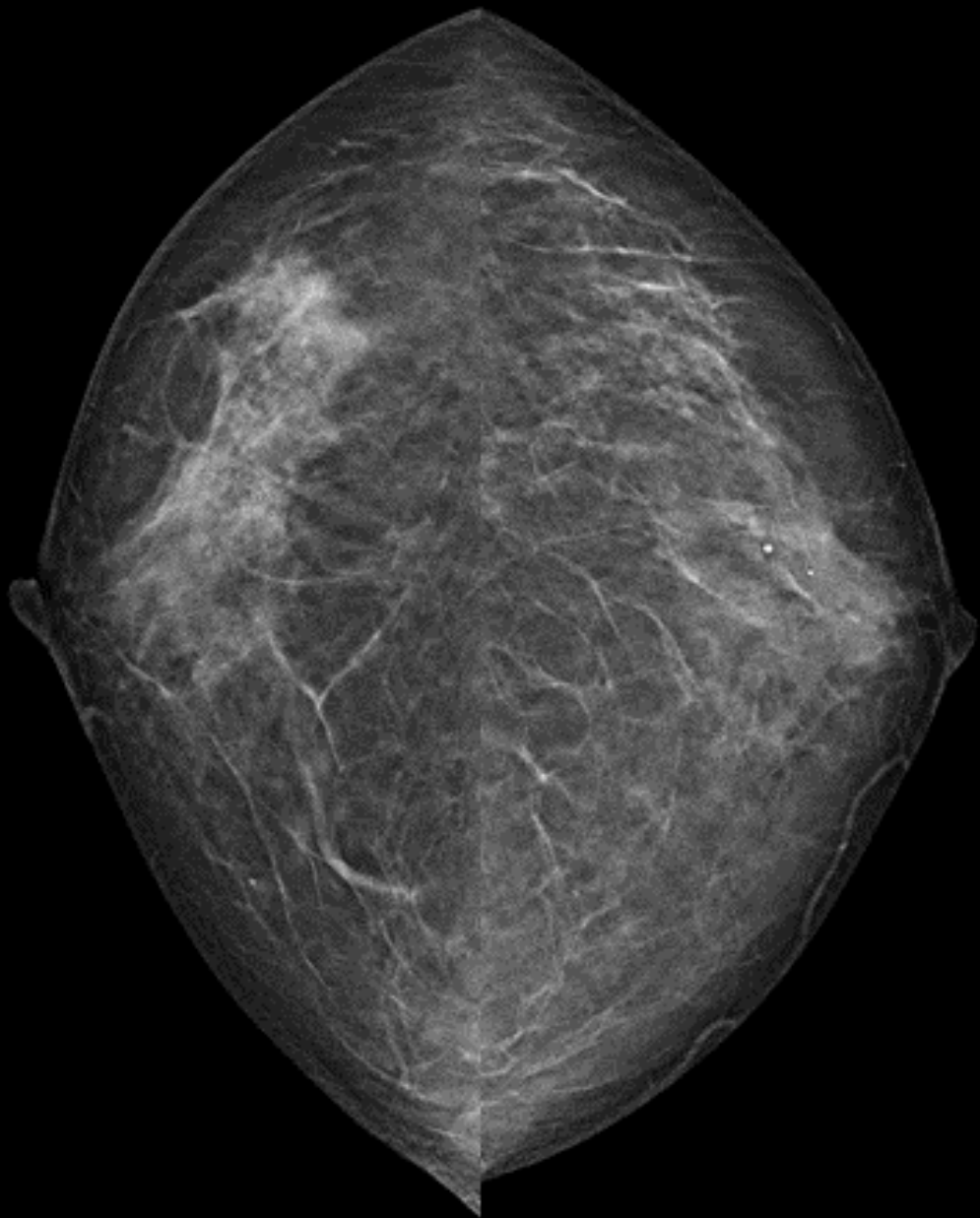
> L cc





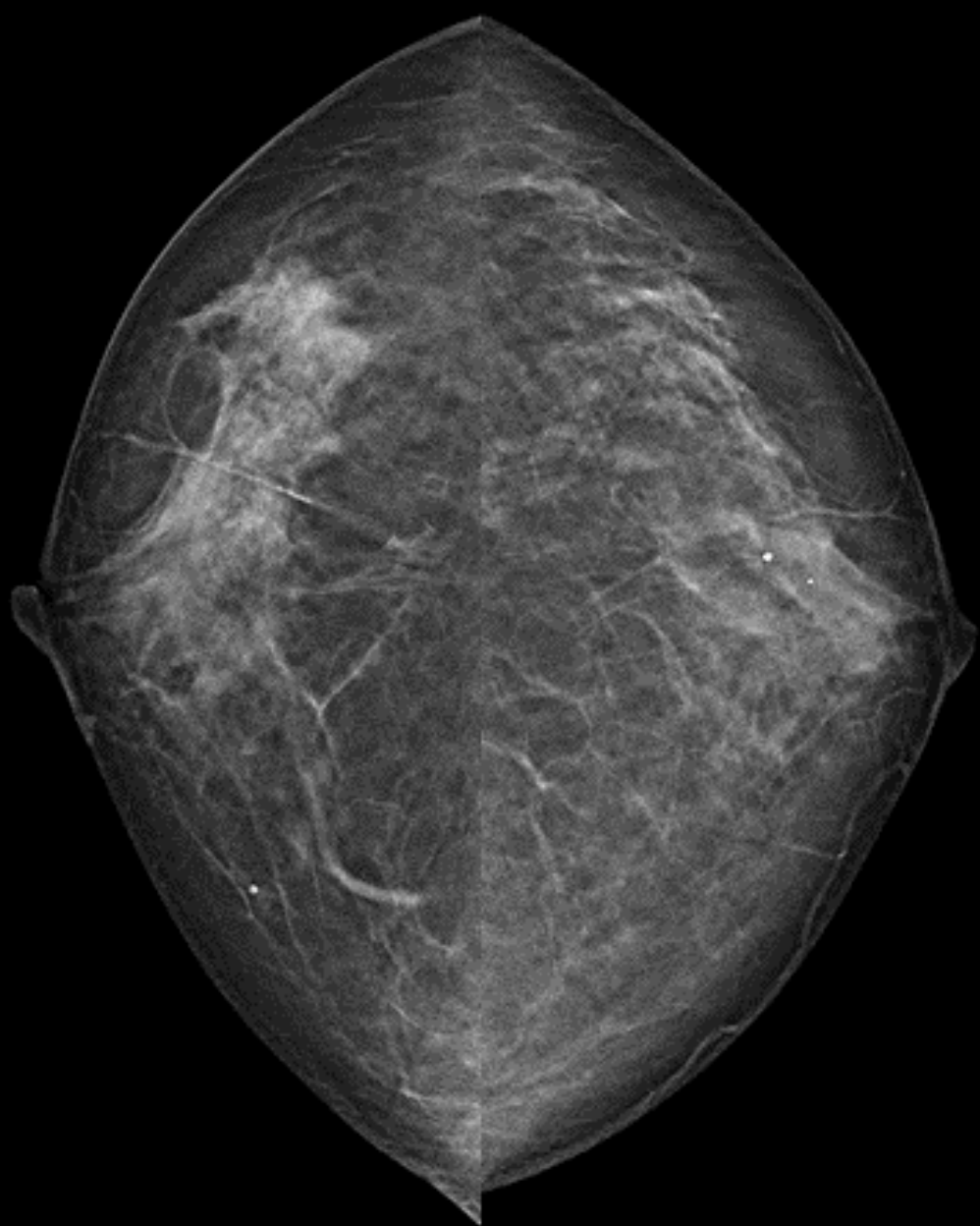
R cc

L cc



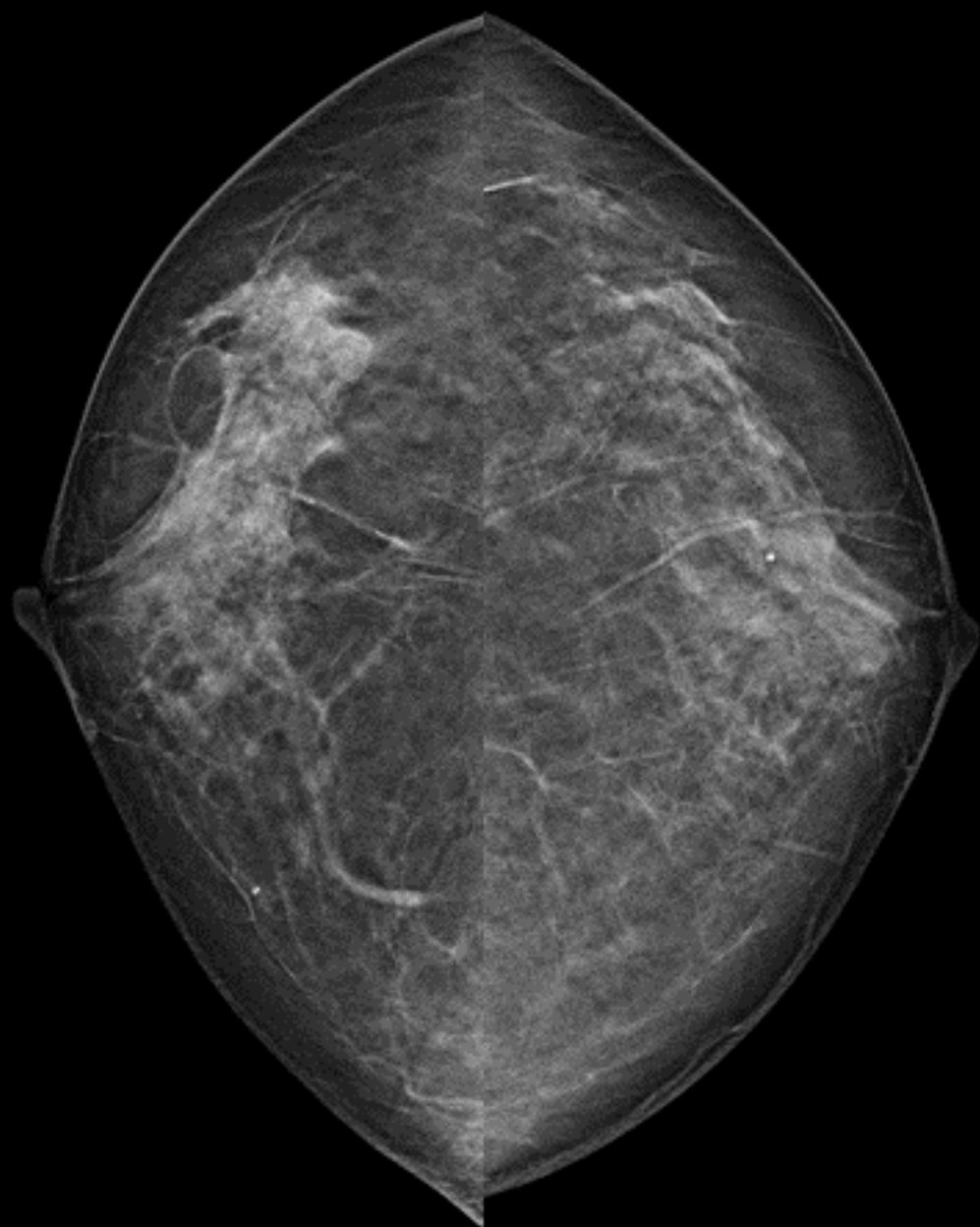
R cc

L cc



R cc

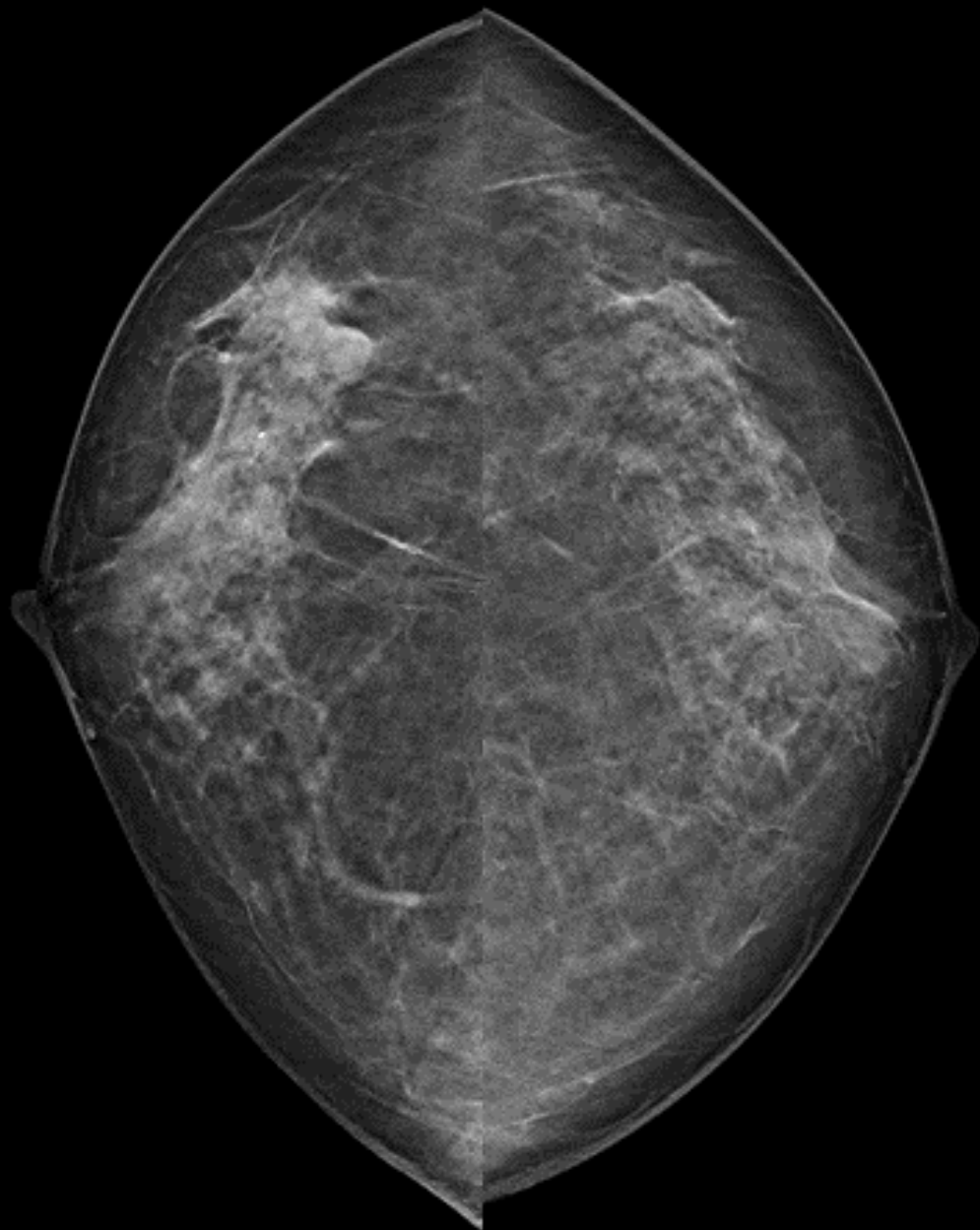
L cc





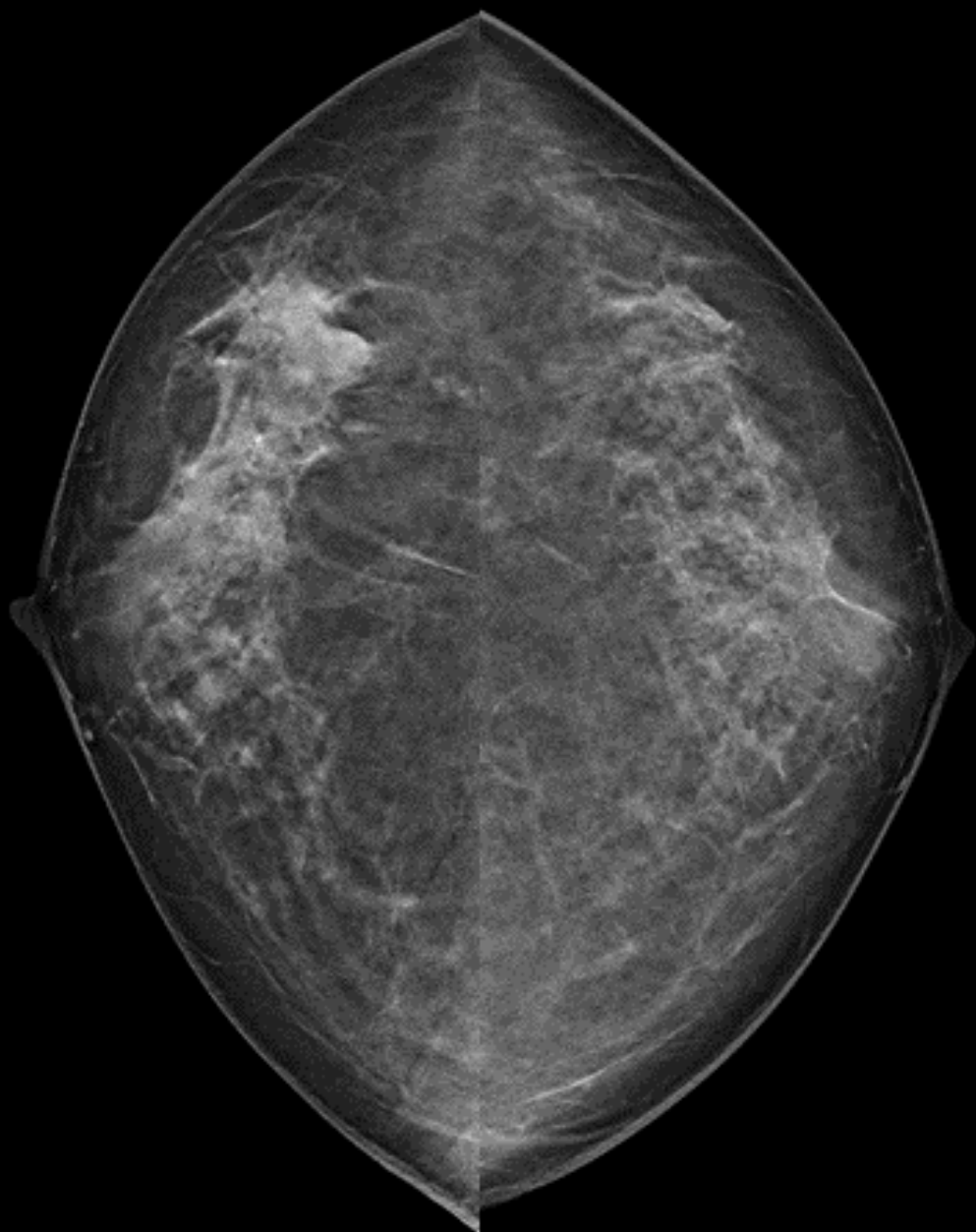
R cc

L cc



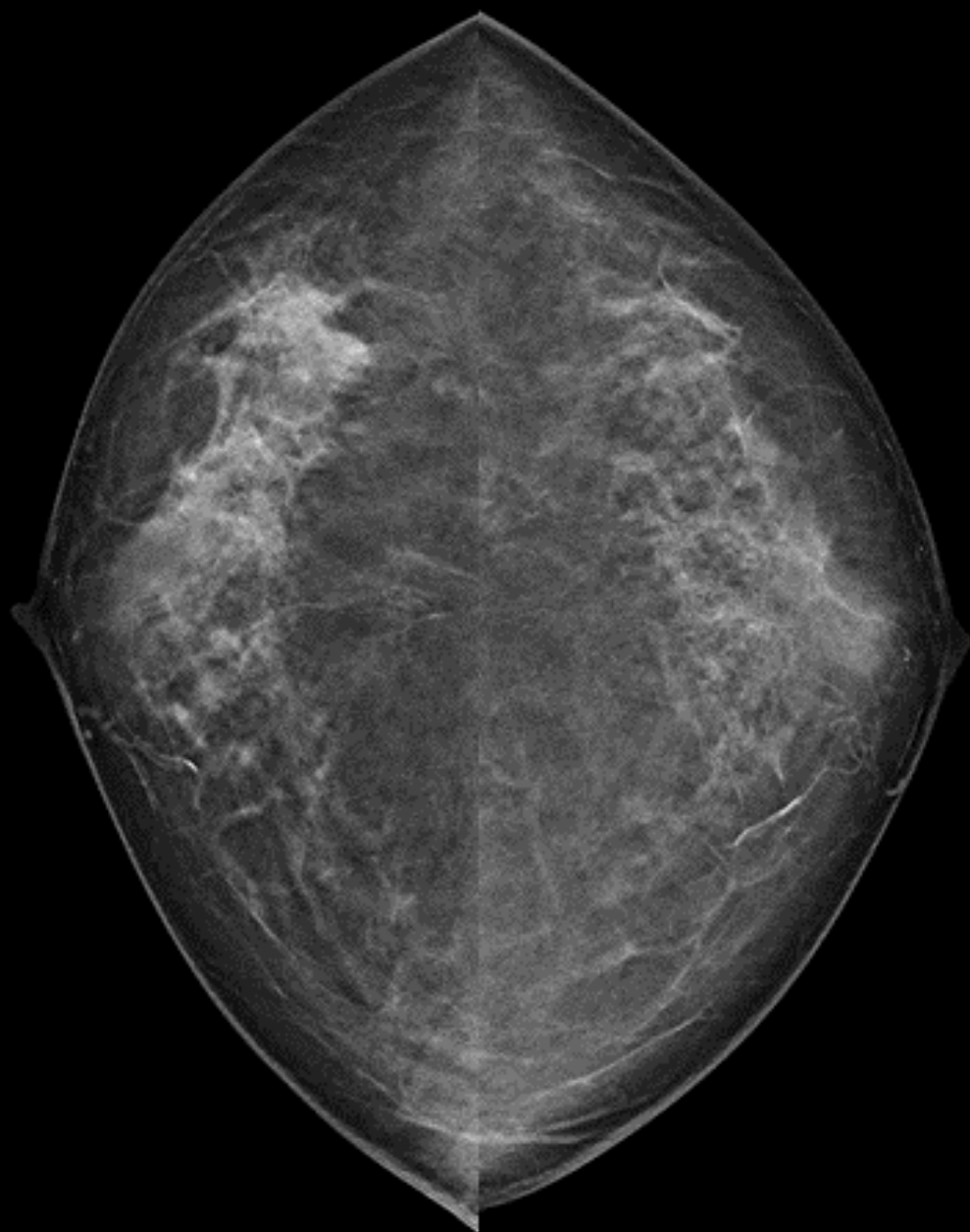
R cc

L cc



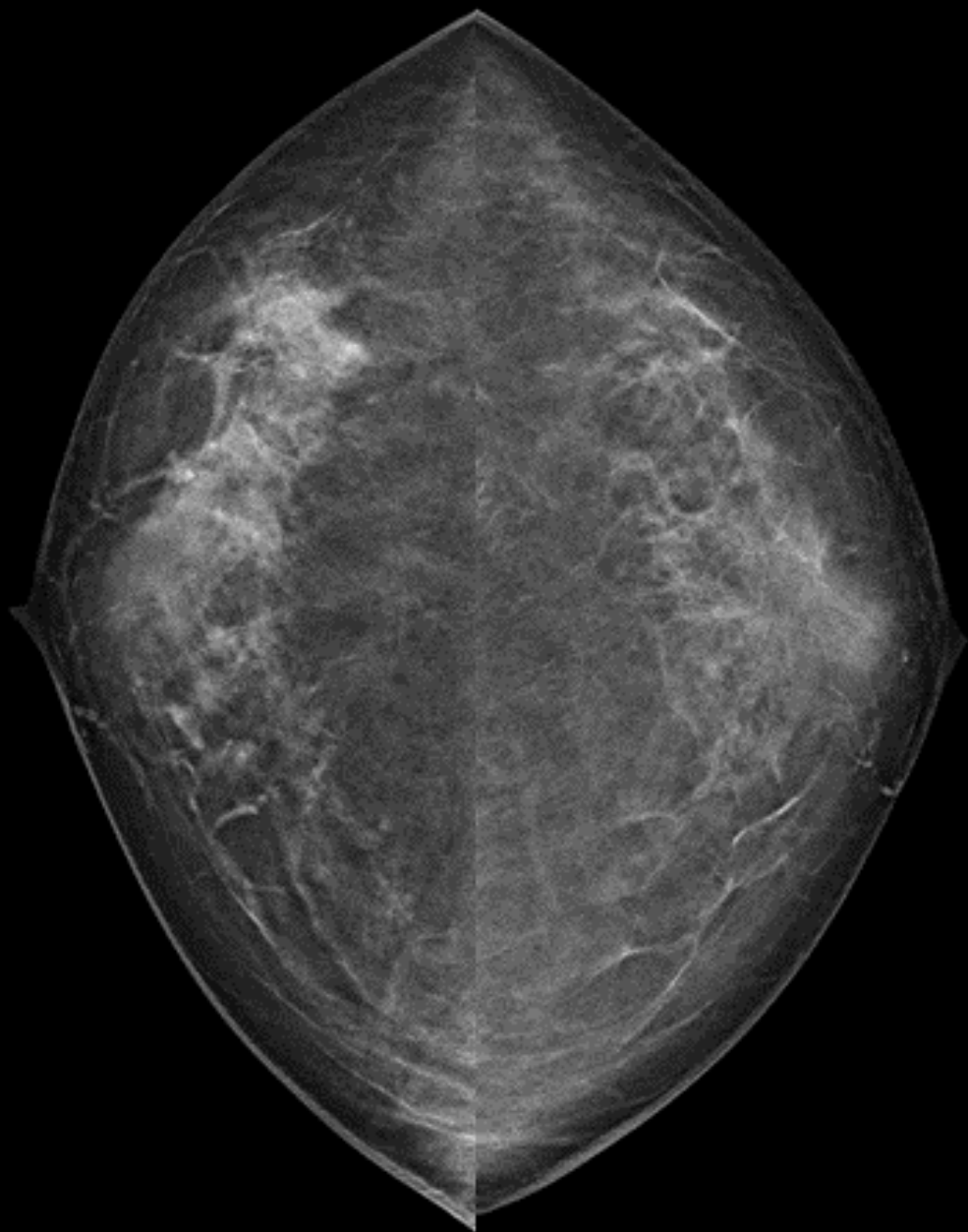
R cc

L cc



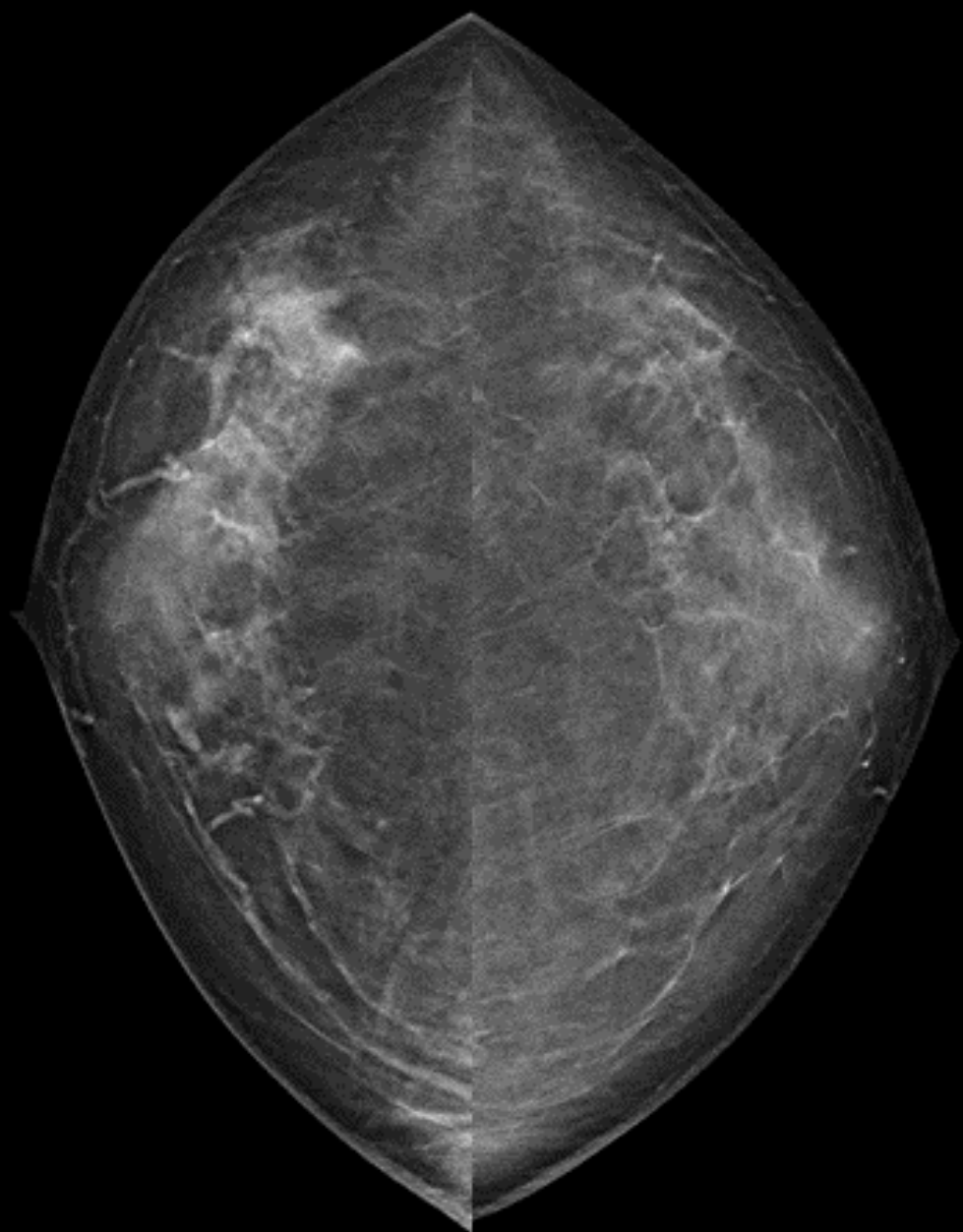
R cc

L cc



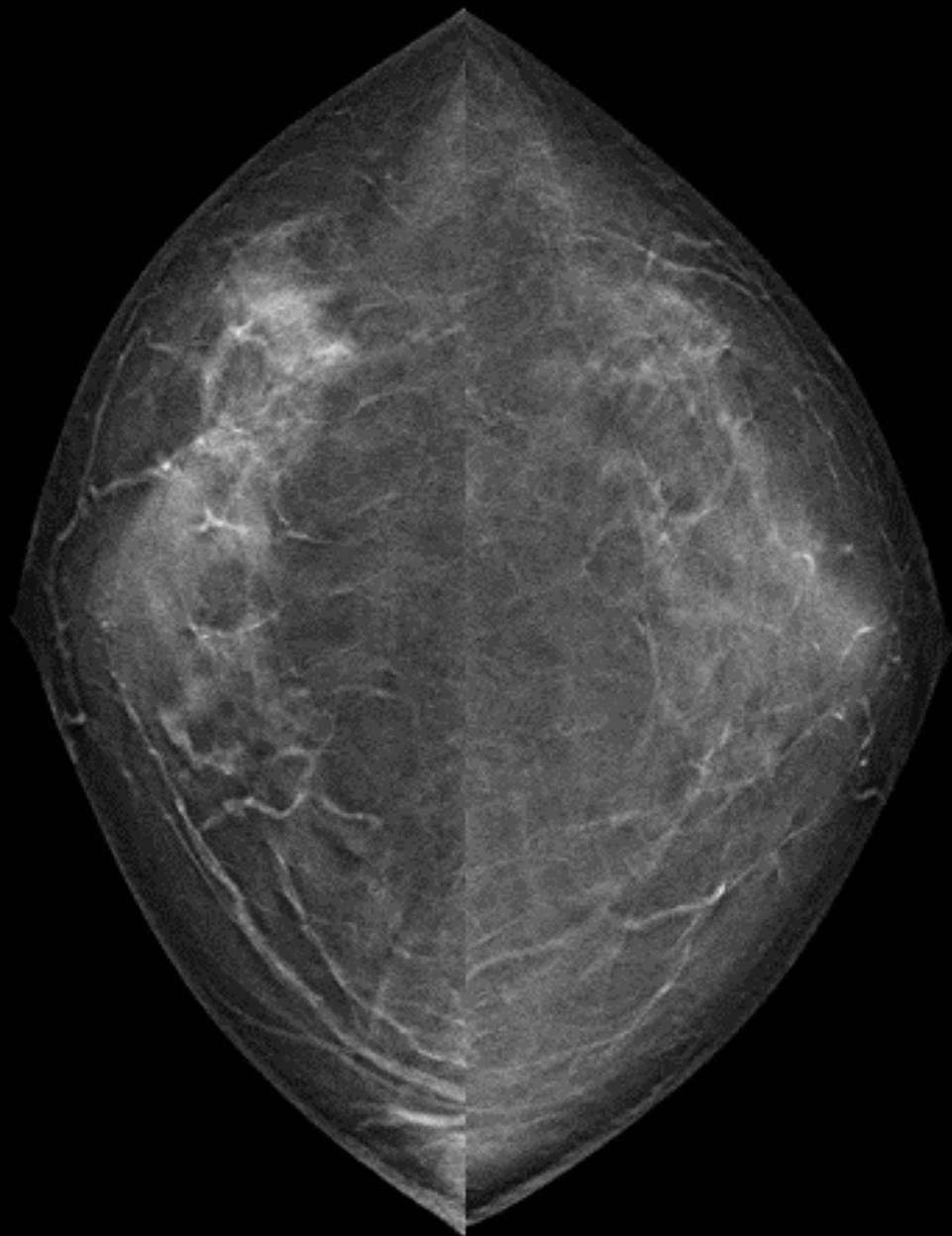
R cc

L cc



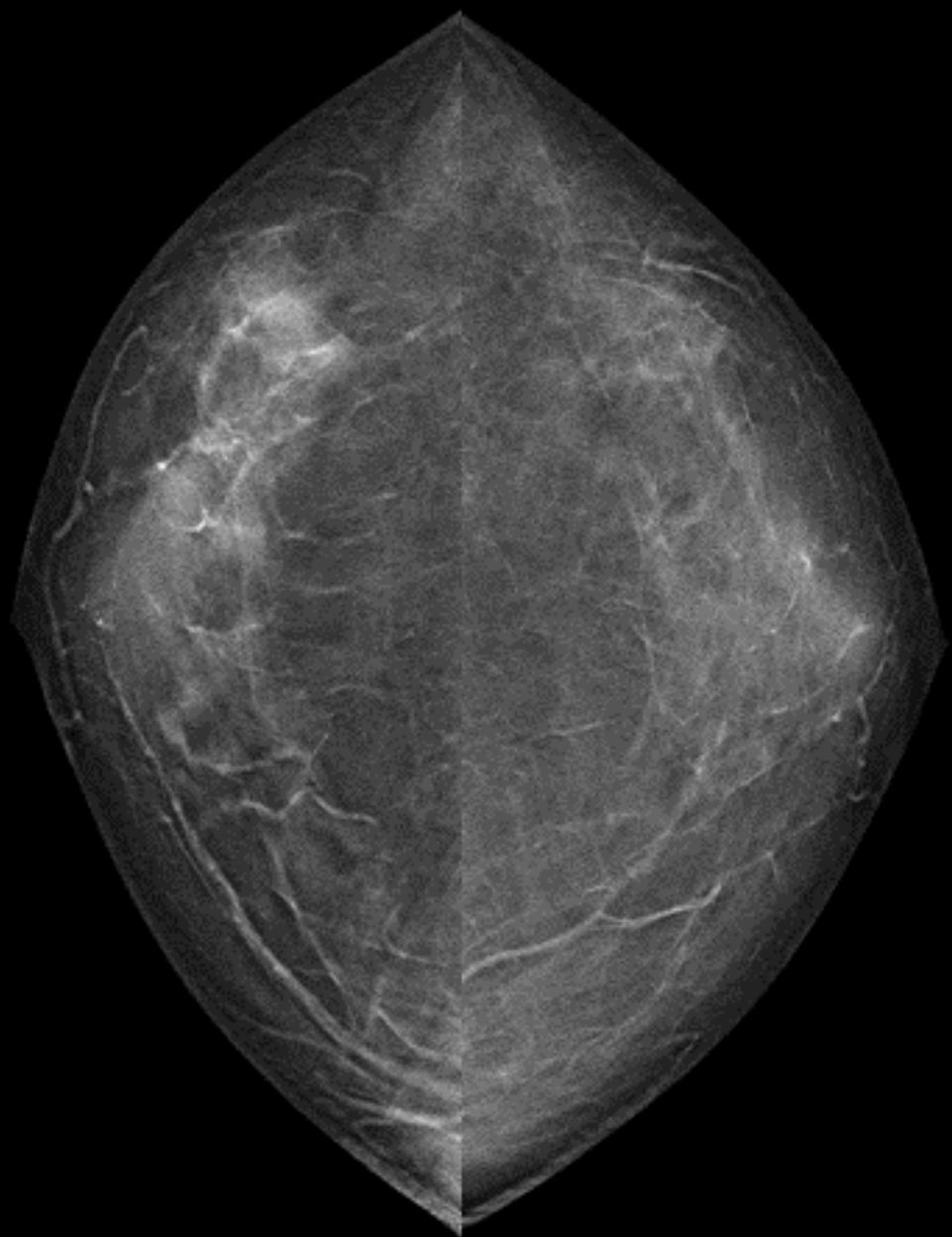
R cc

L cc



R cc

L cc



## 出題内容

### Q1. 検診MG

所見・推定疾患・カテゴリー

### Q2. トモシンセシス

腫瘍なのかFADなのか、病変はどの範囲まであると思うか

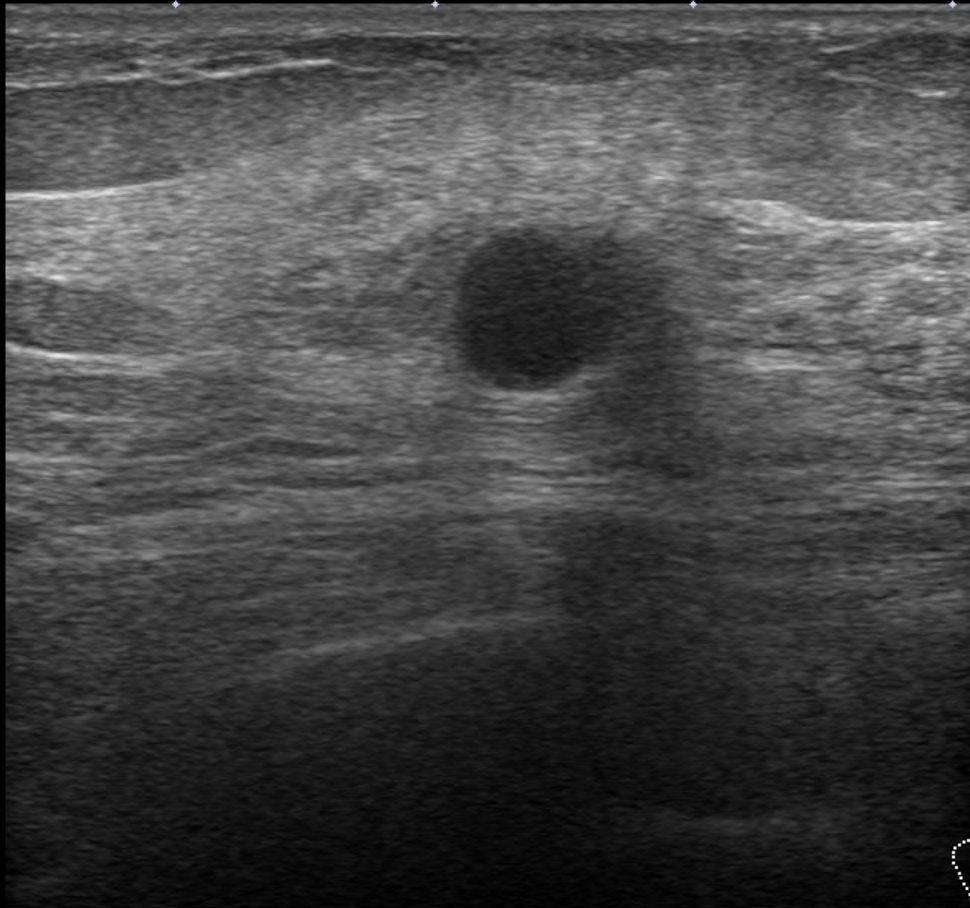
### Q3. US(精査)

所見・推定疾患・浸潤の有無・カテゴリー

### Q4. MRI

ご施設ではどんなシリーズをどんな手順で見ているか





Precision+ APure+

T

0

MI  
(1.6)  
18L7  
d18.0  
35 fps

1

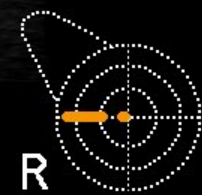G:85  
DR:70

2

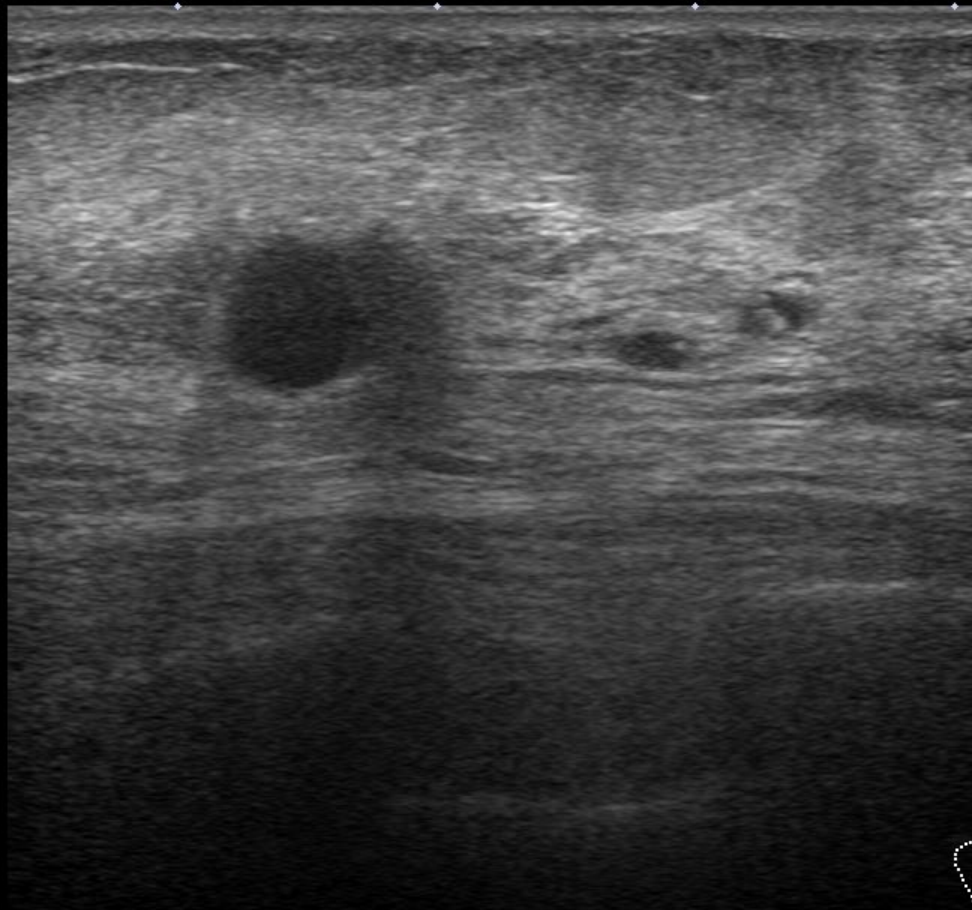
A:4  
P:1

3

3.5



R



Precision+ APure+

T

0

MI  
(1.6)  
18L7  
d18.0  
35 fps

1

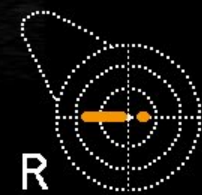G:85  
DR:70

A:4  
P:1

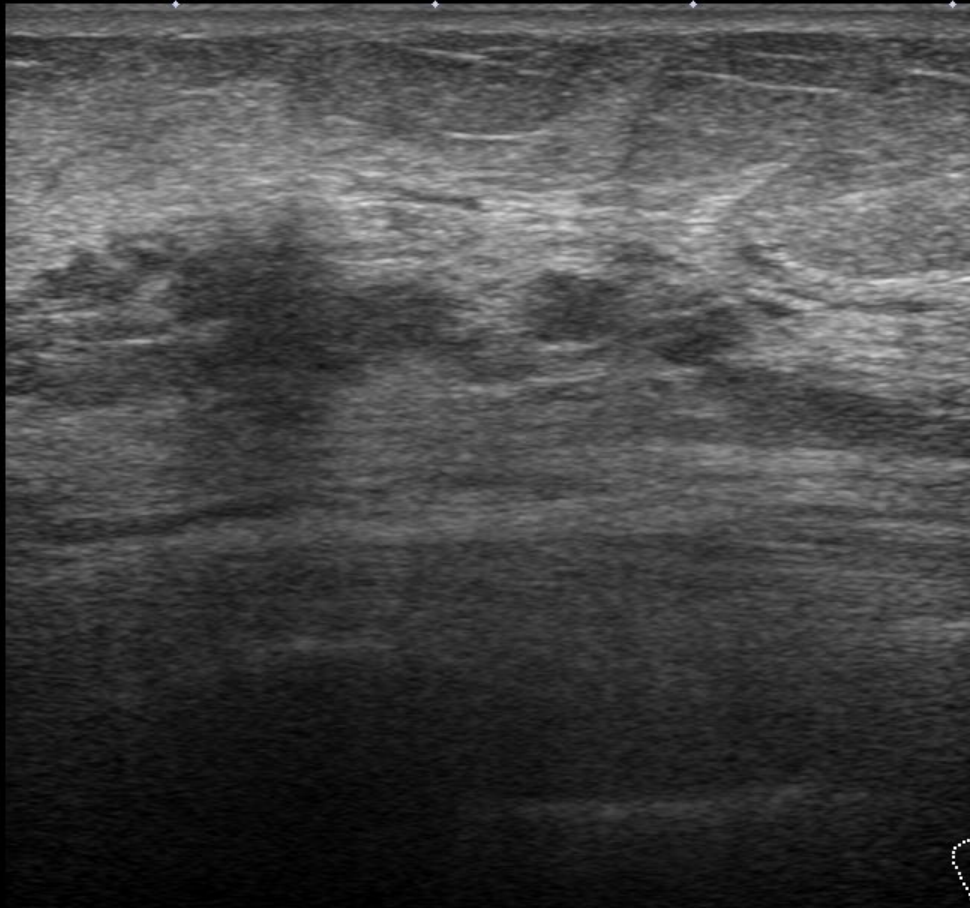
2

3

3.5



R



Precision+ APure+

T

0

MI  
(1.6)  
18L7  
d18.0  
35 fps

1

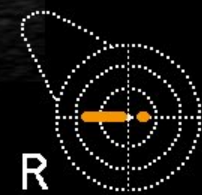G:85  
DR:70

A:4  
P:1

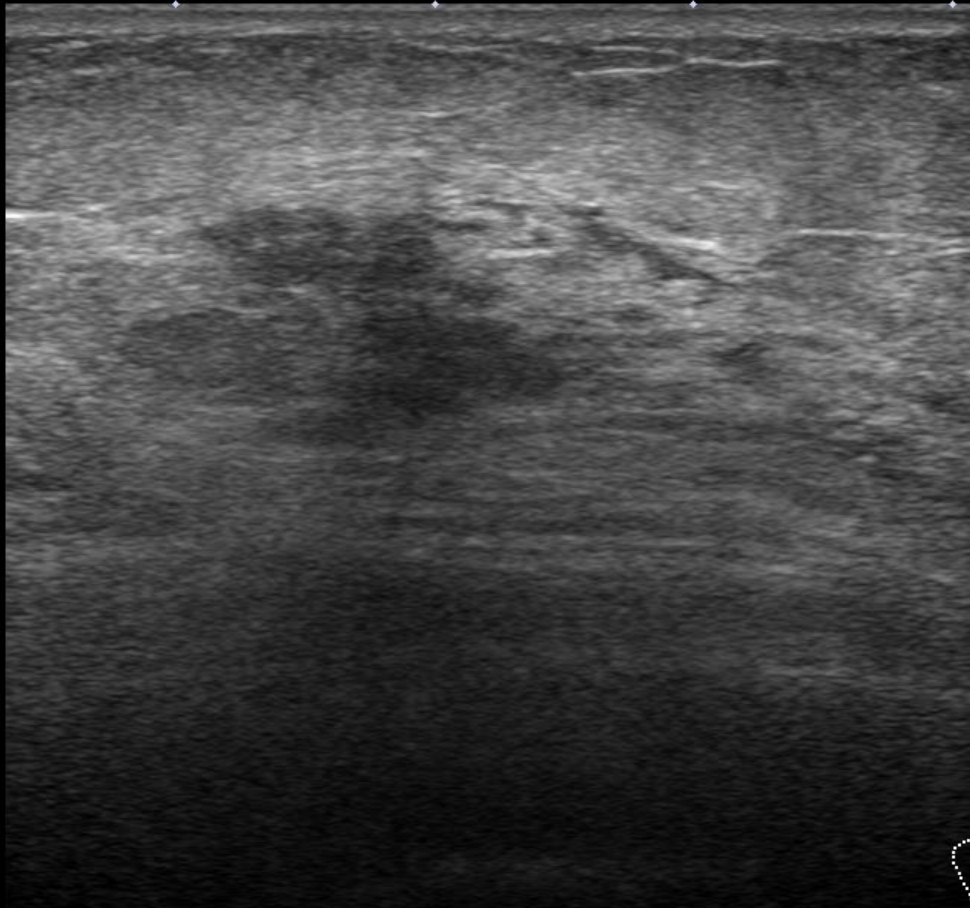
2

3

3.5



R



Precision+ APure+

T

0

MI  
(1.6)  
18L7  
d18.0  
35 fps

1

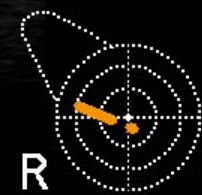G:85  
DR:70

A:4  
P:1

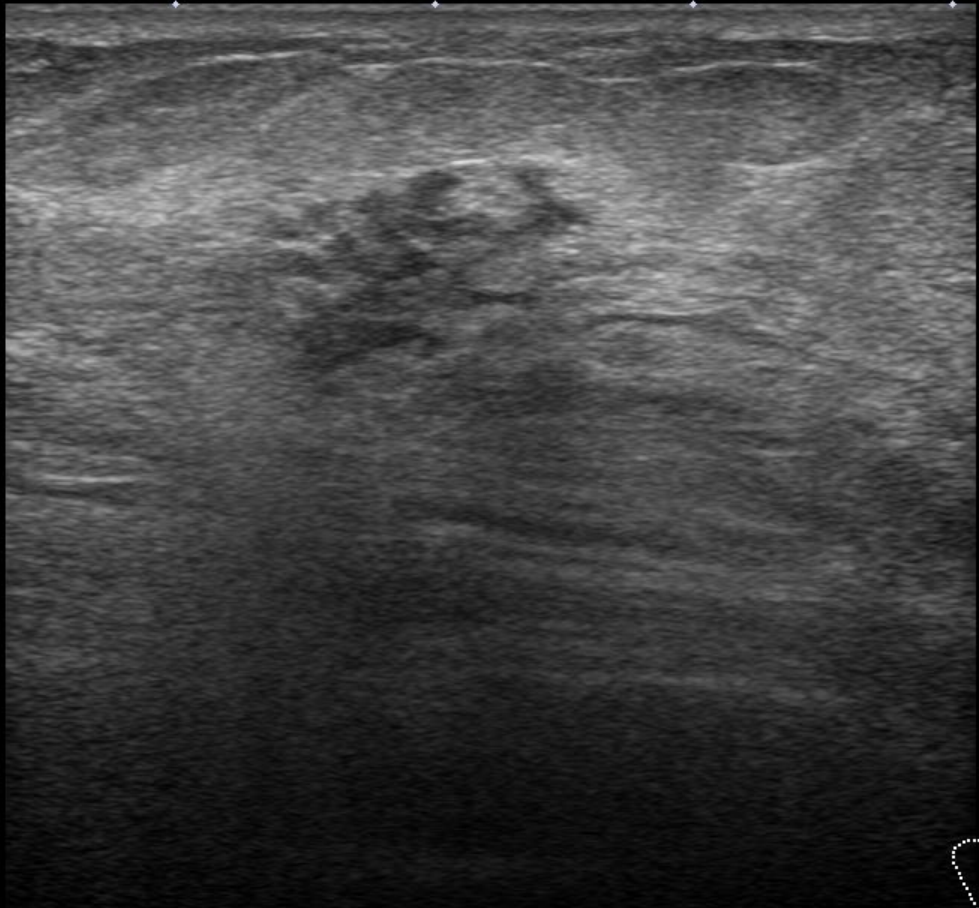
2

3

3.5



R



Precision+ APure+

T

0

MI  
(1.6)  
18L7  
d18.0  
35 fps

1

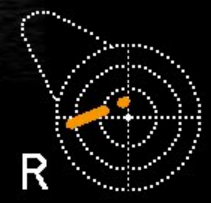G:85  
DR:70

A:4  
P:1

2

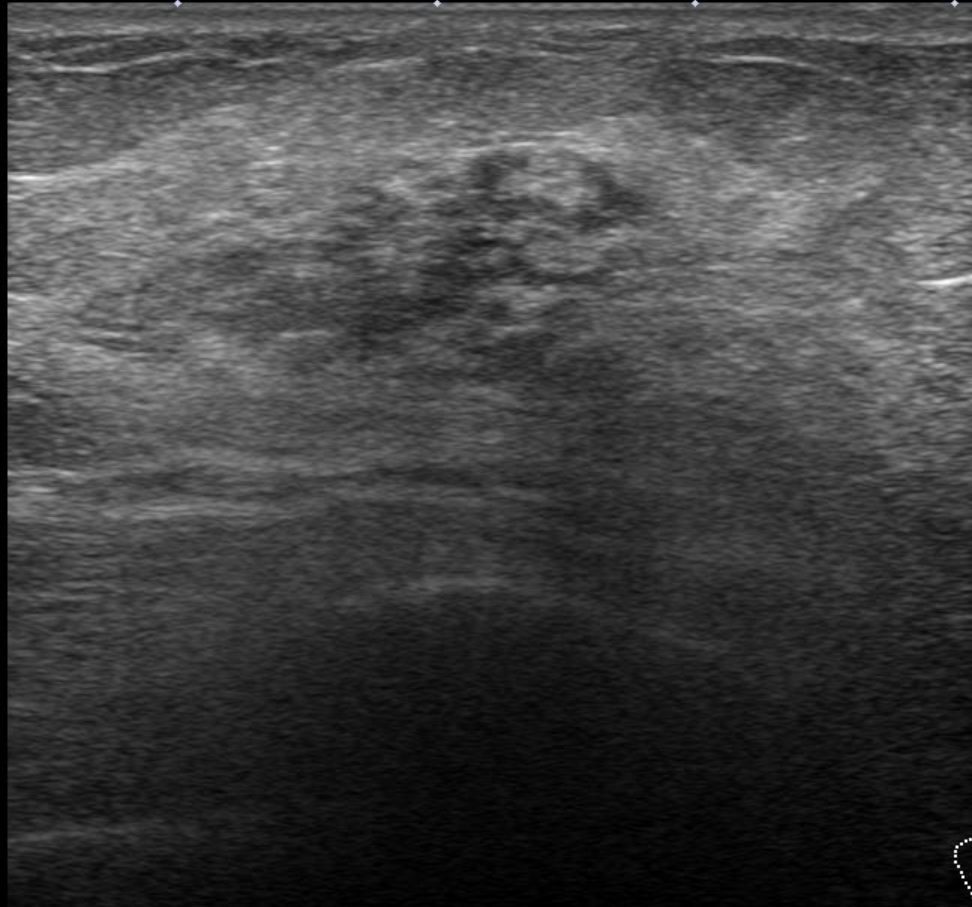
3

3.5



R





Precision+ APure+

T

◇ 0

MI  
(1.6)  
18L7  
d18.0  
35 fps

◇ 1

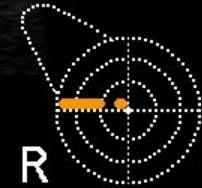G:85  
DR:70

◇ 2

A:4  
P:1

◇ 3

◇ 3.5



R

A Pure+ Precision+



Precision+ A Pure+



MI  
(1.6)  
18L7  
d18.0  
35 fps

G:85  
DR:70

A:4  
P:1

MI  
(1.6)  
18L7  
d18.0  
35 fps

G:85  
DR:70

A:4  
P:1

0

0

1

1

2

2

3

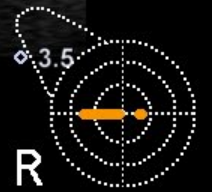3

3.5

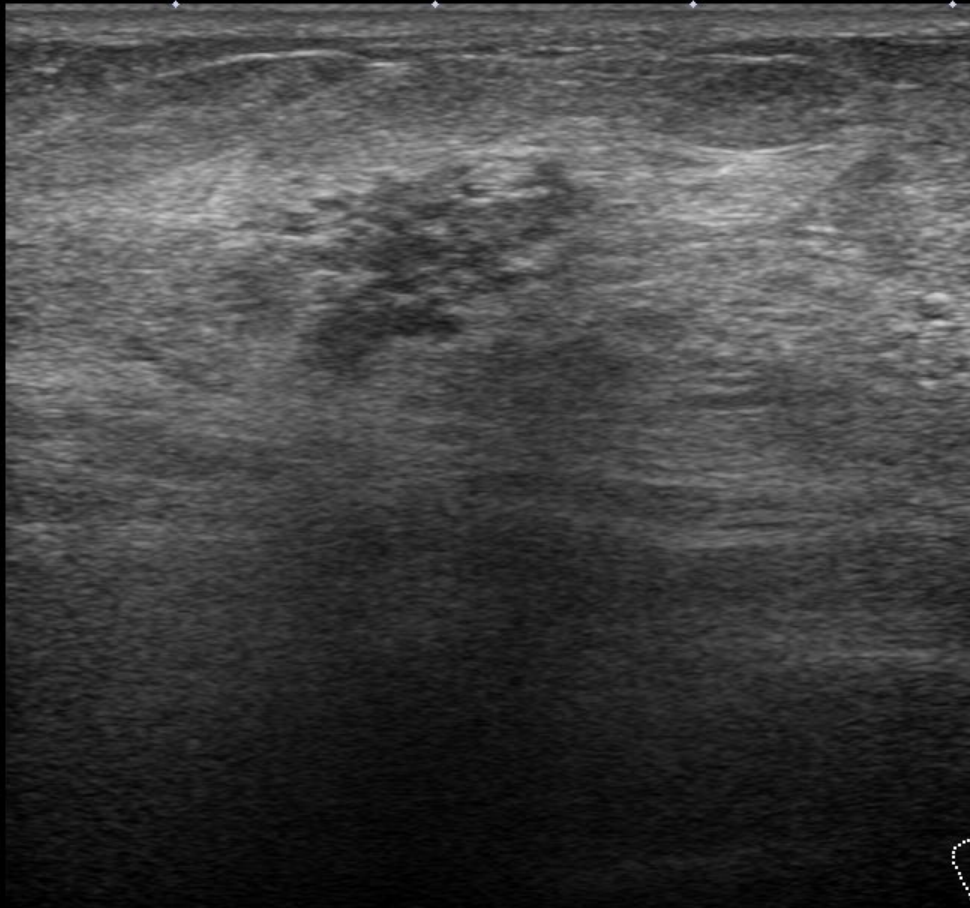
3.5



R



R



Precision+ APure+

T

0

MI  
(1.6)  
18L7  
d18.0  
35 fps

1

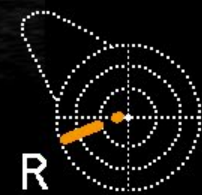G:85  
DR:70

2

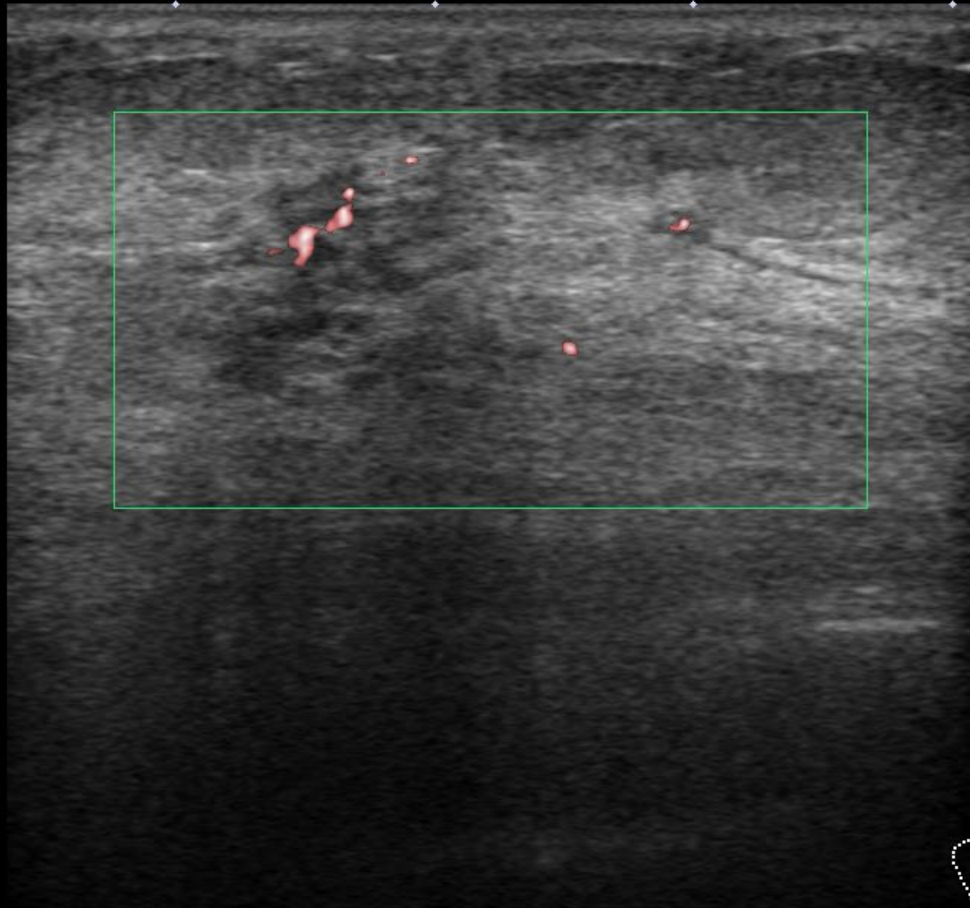
A:4  
P:1

3

3.5







Precision+ APure

T

0

1.5

MI  
(1.6)  
18L7  
d18.0  
58 fps

1

G:85  
DR:70



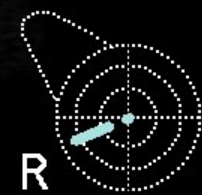SMI 6.0  
CG:40

F:3

2

3

3.5



R

A Pure+ Precision+

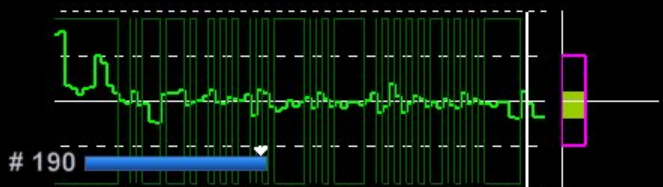
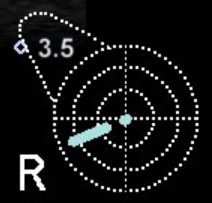T

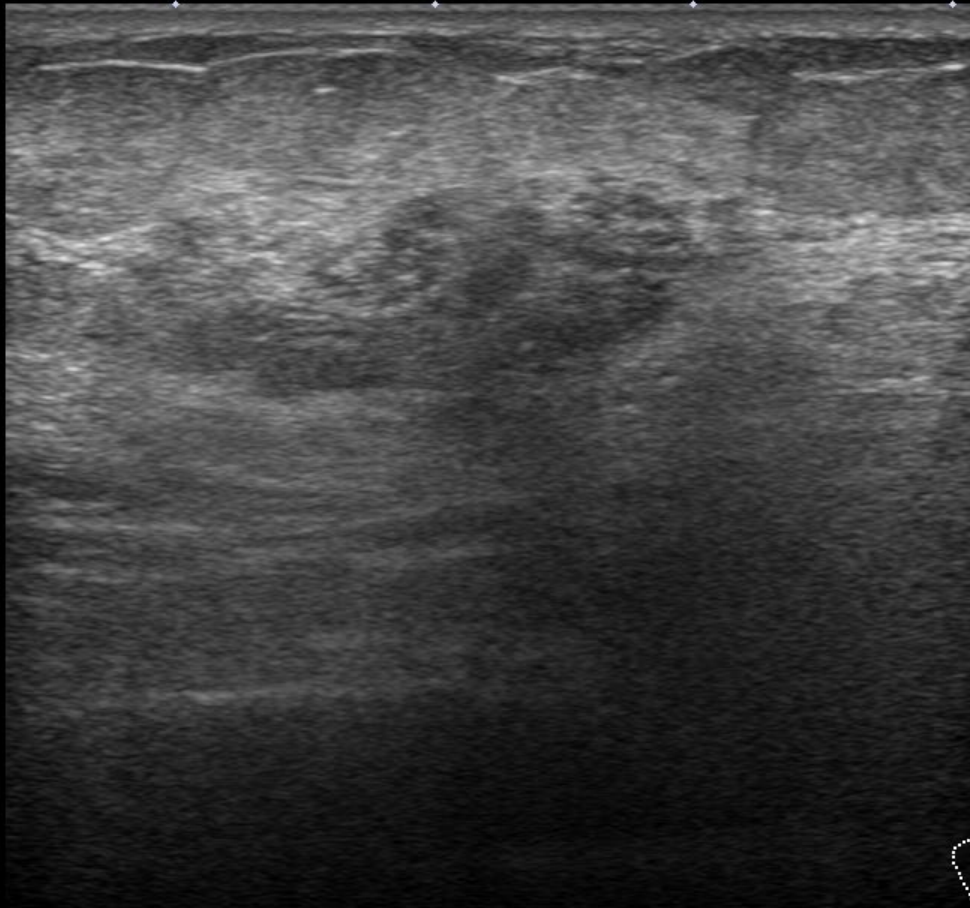
Precision+ A Pure+

T

Soft  
MI (1.6)  
18L7  
d18.0  
26 fps  
G:85  
DR:70  
Hard  
CF 6.0  
CG:60  
0.28  
cm/s

18L7  
d18.0  
26 fps  
G:85  
DR:70  
A:4  
P:1





Precision+ APure+

T

0

MI  
(1.6)  
18L7  
d18.0  
35 fps

1

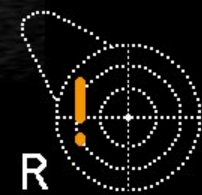G:85  
DR:70

A:4  
P:1

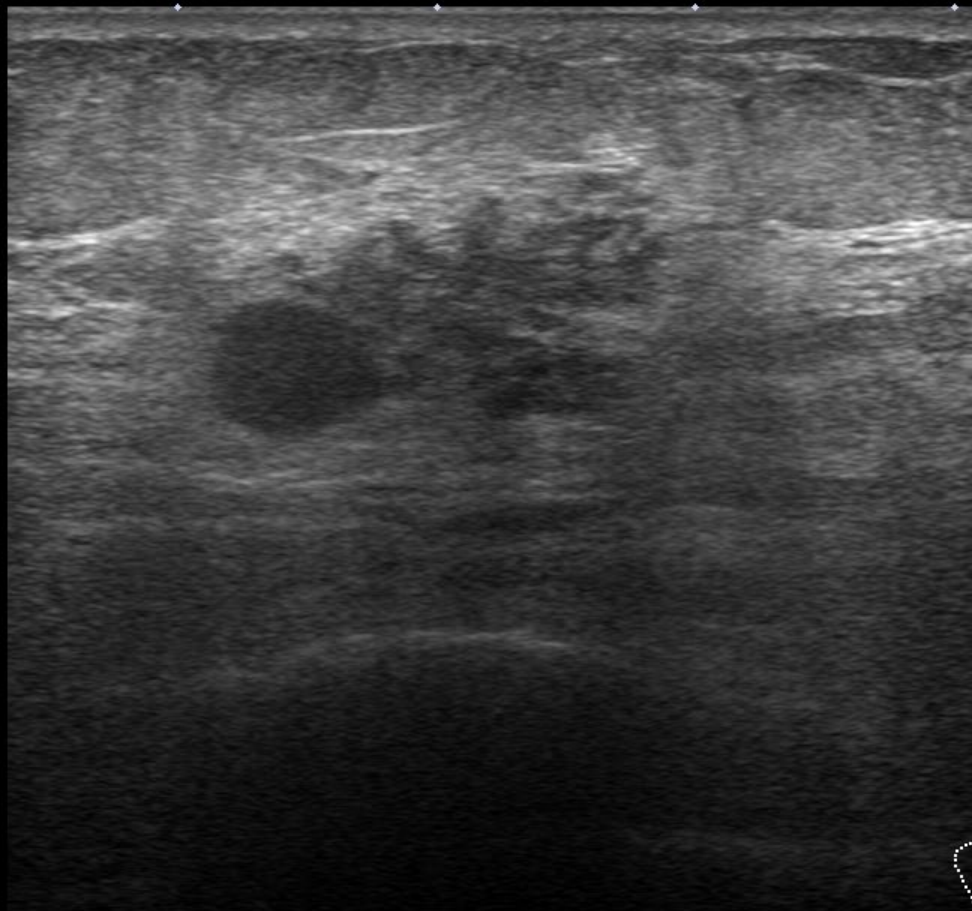
2

3

3.5



R



Precision+ APure+

T

◇ 0

MI (1.6)  
18L7  
d18.0  
35 fps

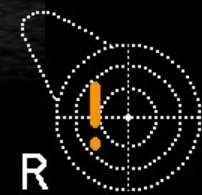◇ 1 G:85  
DR:70

A:4  
P:1

◇ 2

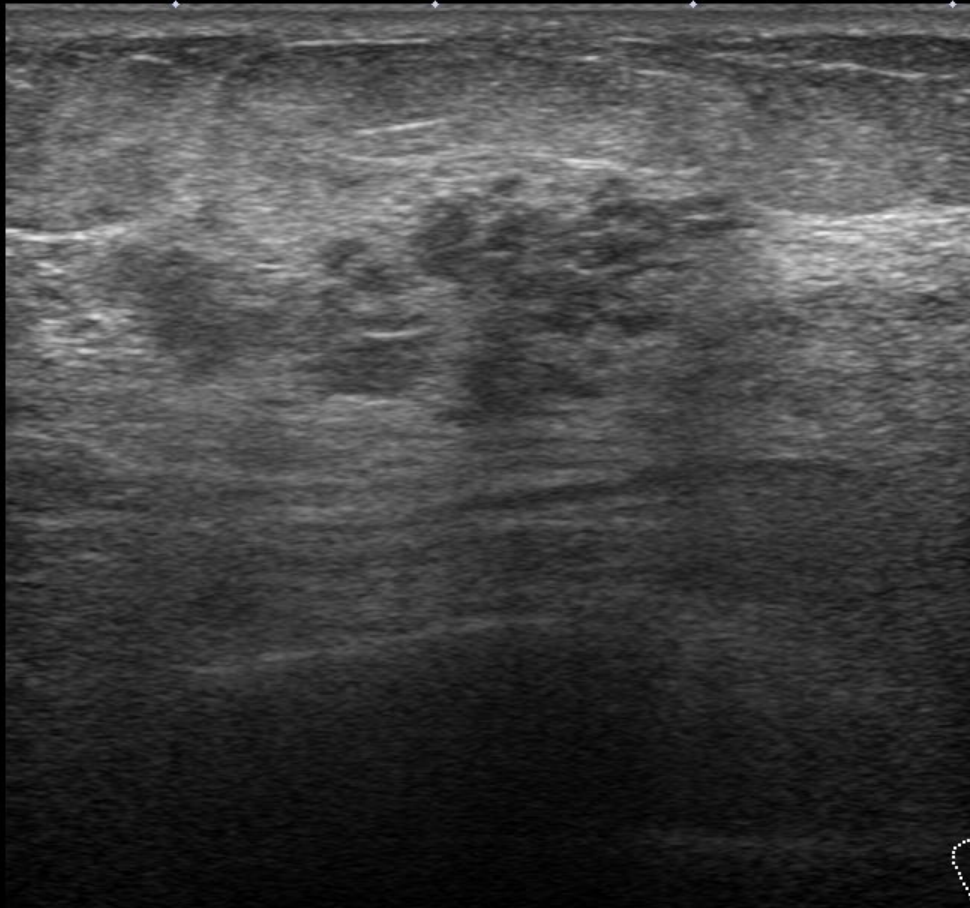
◇ 3

◇ 3.5



R





Precision+ APure+

T

◇ 0

MI  
(1.6)  
18L7  
d18.0  
35 fps

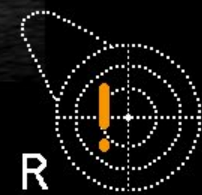◇ 1  
▶ G:85  
DR:70

◇ A:4  
P:1

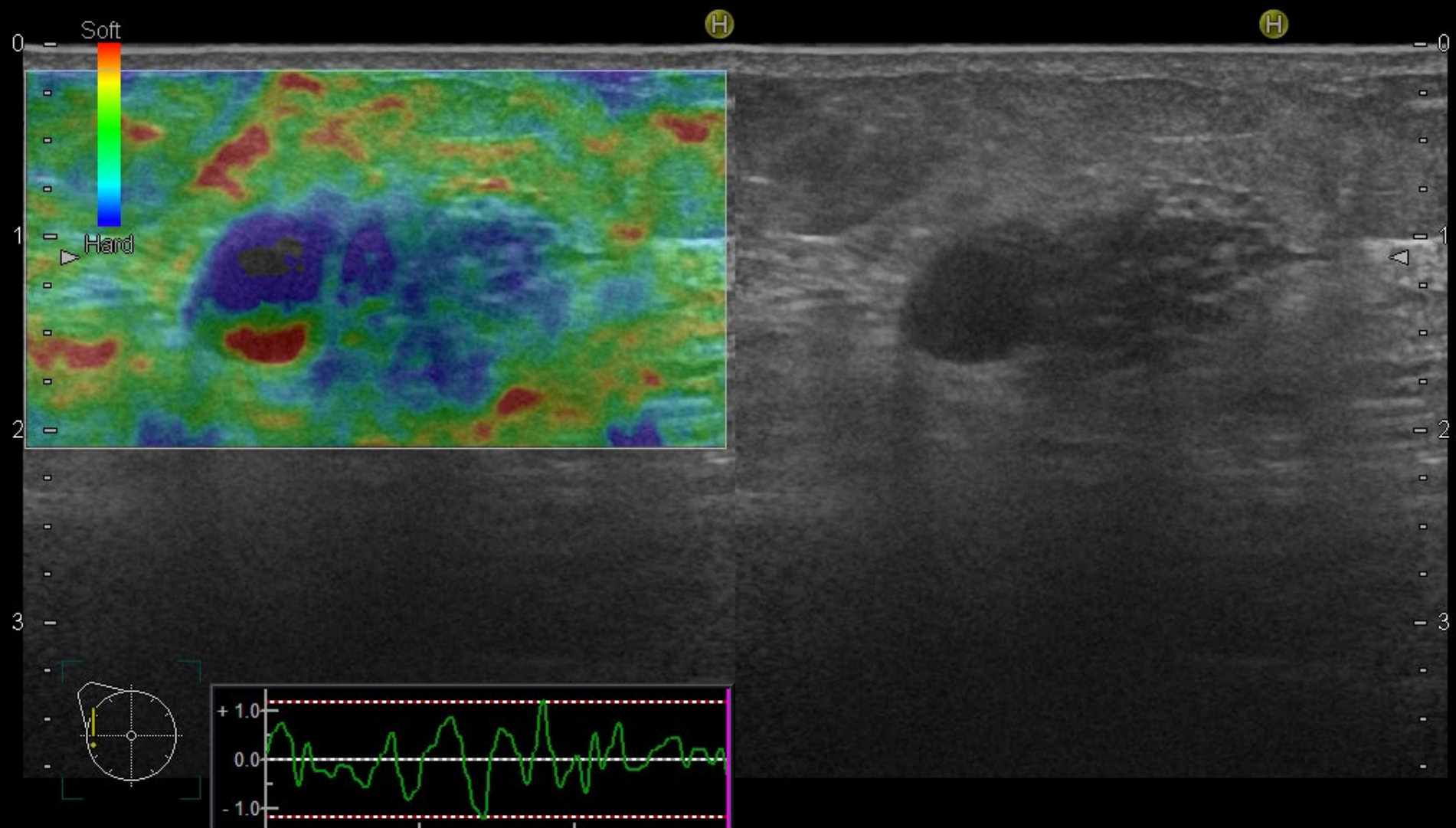
◇ 2

◇ 3

◇ 3.5



R

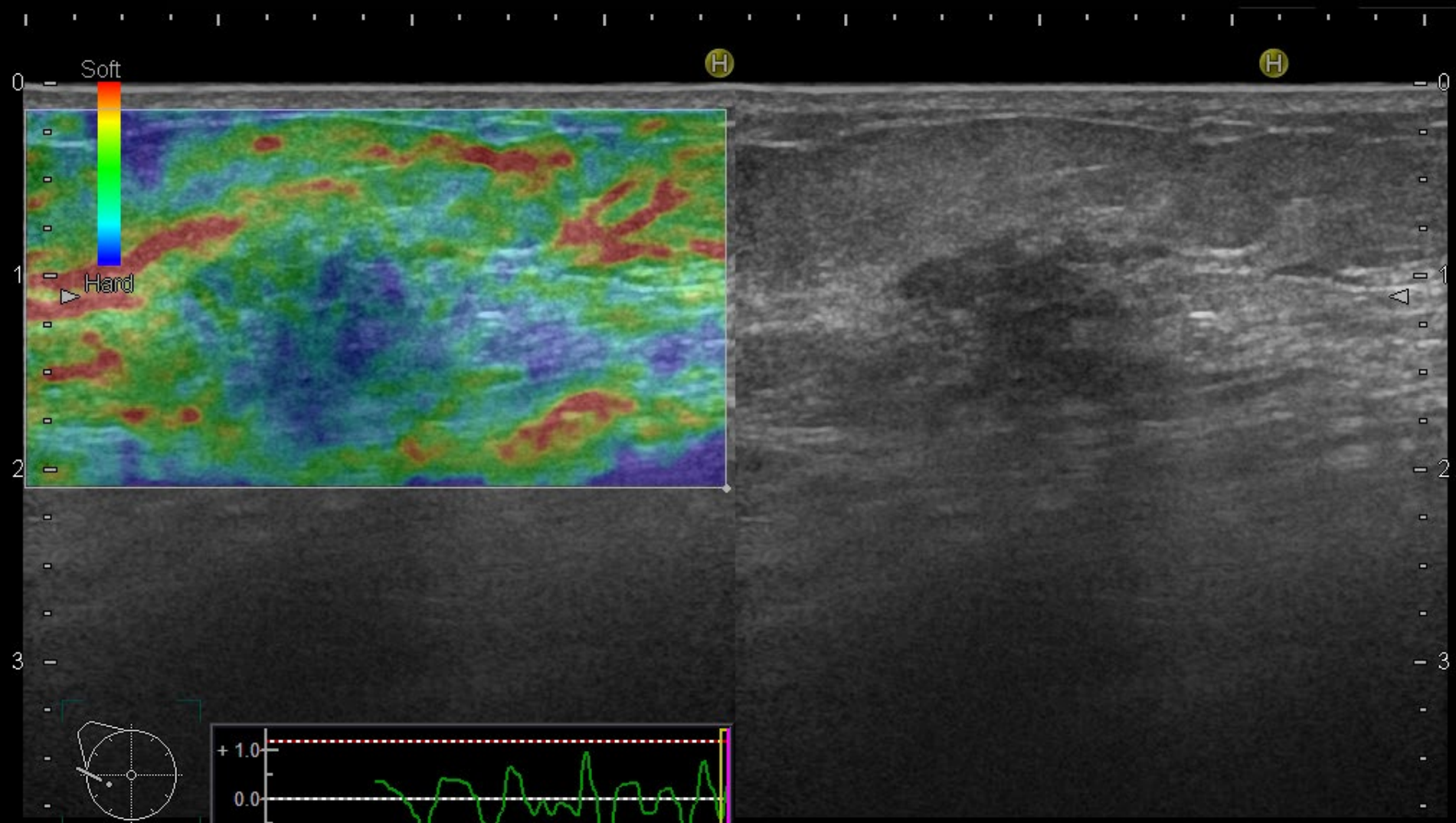


FR:18  
L75

BG:19 DR:75 F.Rej:5 N.Rej:3  
18MHz BL.:26%

FR:18  
L75

BG:19 DR:75  
18MHz



FR:18  
L75

BG:19 DR:75 F.Rej:5 N.Rej:3  
18MHz BL.:26%

FR:18  
L75

BG:19 DR:75  
18MHz

## 出題内容

### Q1. 検診MG

所見・推定疾患・カテゴリー

### Q2. トモシンセシス

腫瘍なのかFADなのか、病変はどの範囲まであると思うか

### Q3. US(精査)

所見・推定疾患・浸潤の有無・カテゴリー

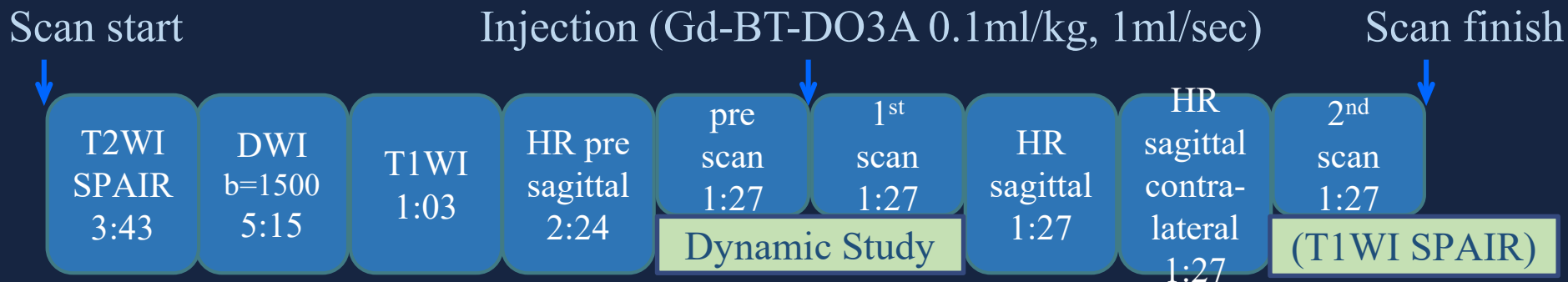
### Q4. MRI

ご施設ではどんなシリーズをどんな手順で見ているか  
(自施設の撮影プロトコルを理解するだけでもよい)



MRI 撮影装置: ?・・・(1.5または3T) (例)

## 撮影プロトコル



早期相 ( 秒)

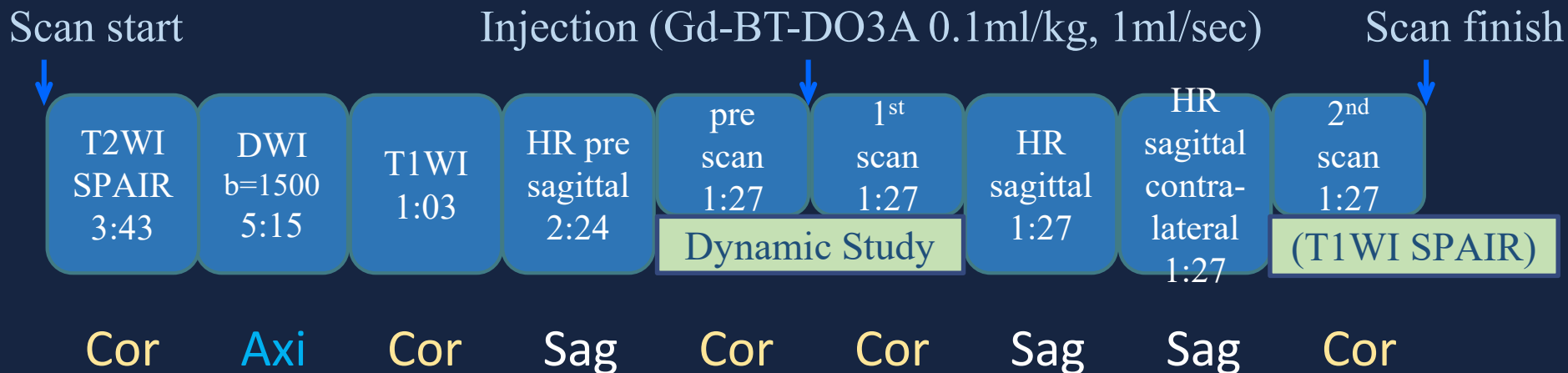
後期相 ( 分)

Axial ? Coronal ?



MRI 撮影装置: Ingenia 3T (Philips)

## 撮影プロトコル

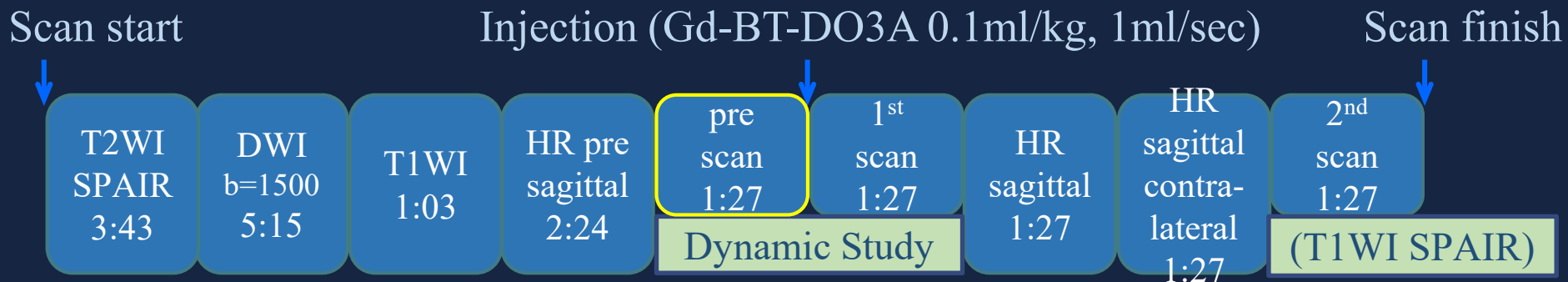


名古屋医療センターの例

Cor 冠状断  
Axi 軸位断  
Sag 矢状断

MRI 撮影装置: Ingenia 3T (Philips)

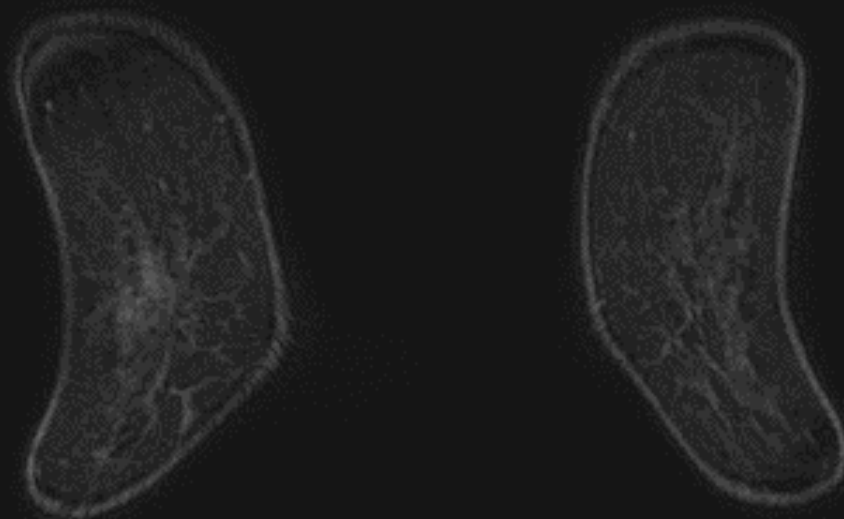
## 撮影プロトコル



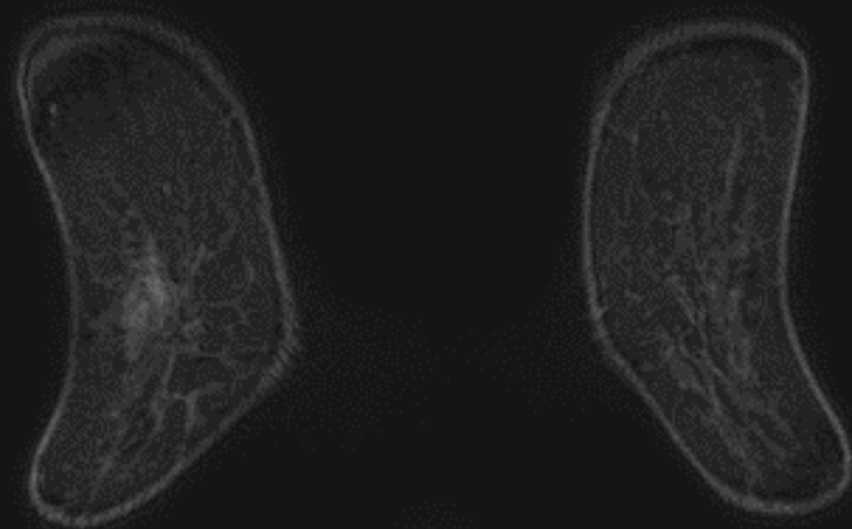
pre (T1WI)

脂肪抑制T1強調画像(造影前)

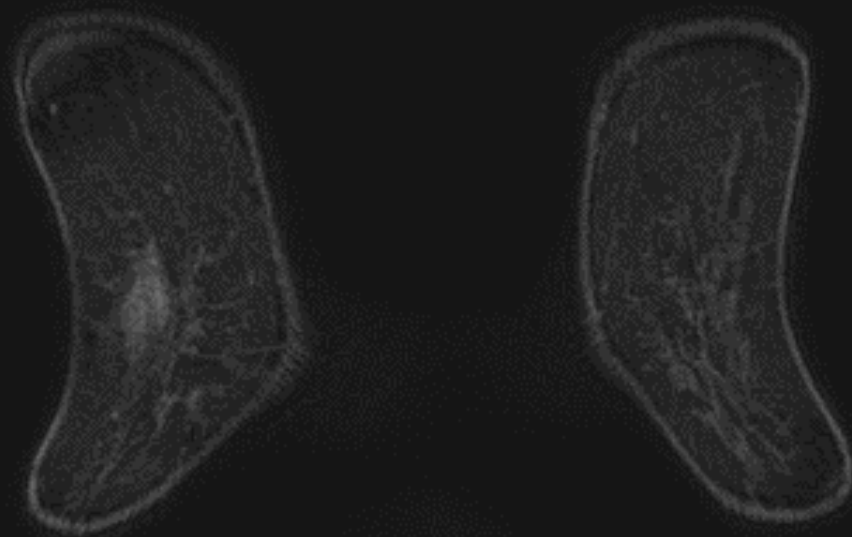
脂肪抑制されたT1WI（造影前）



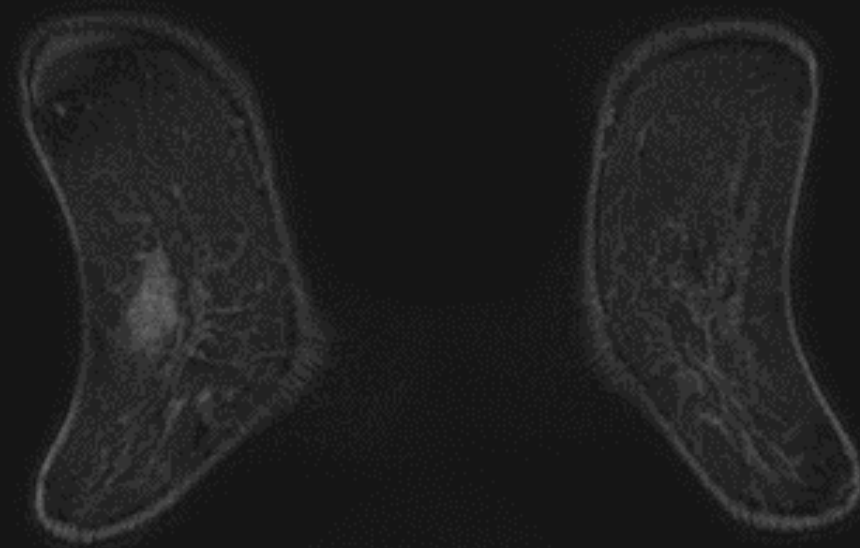
脂肪抑制されたT1WI（造影前）



脂肪抑制されたT1WI（造影前）

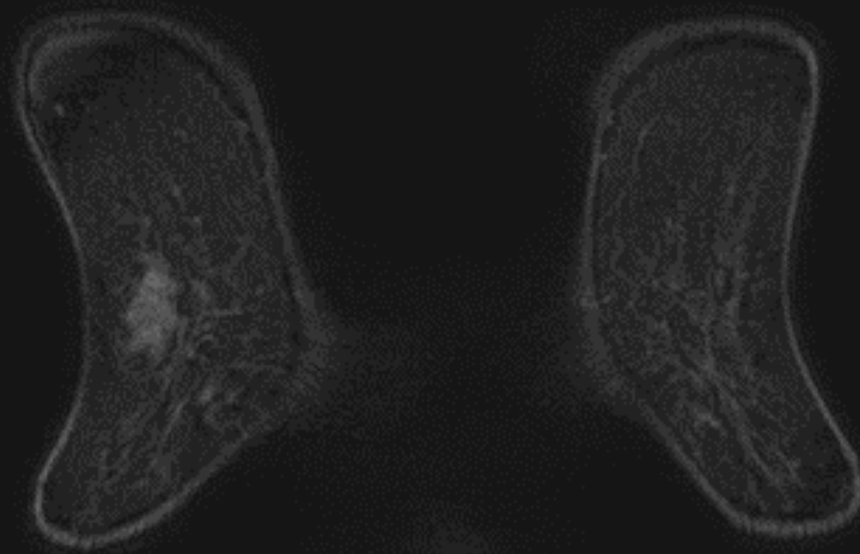


脂肪抑制されたT1WI（造影前）

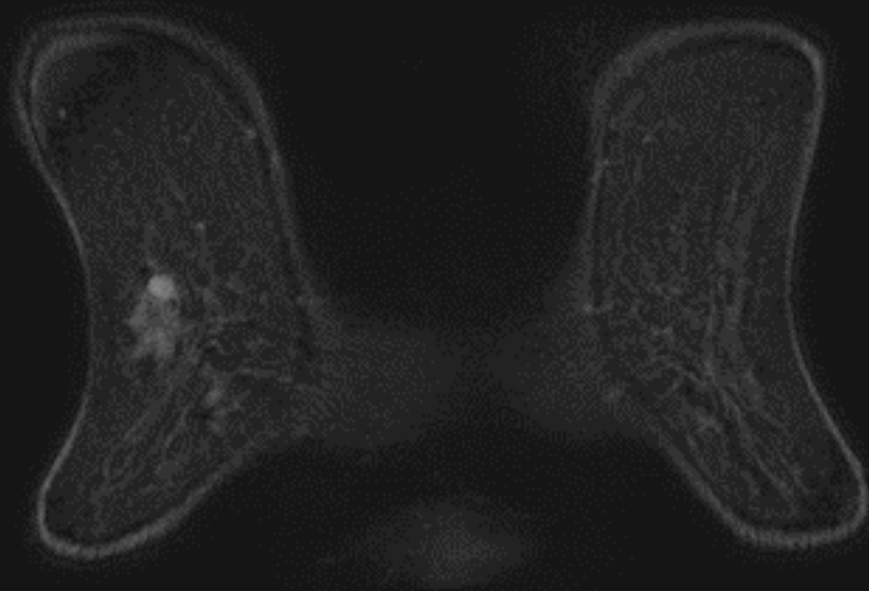




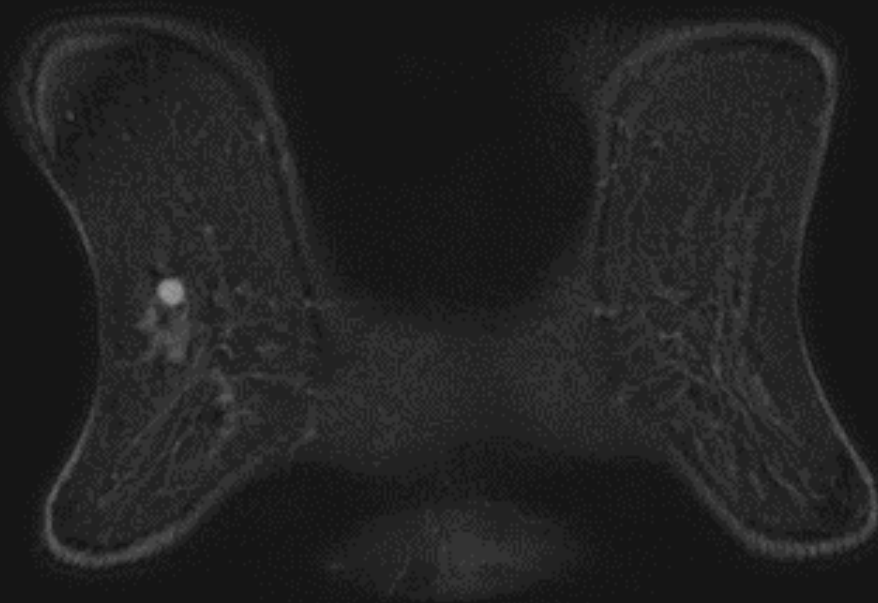
脂肪抑制されたT1WI（造影前）



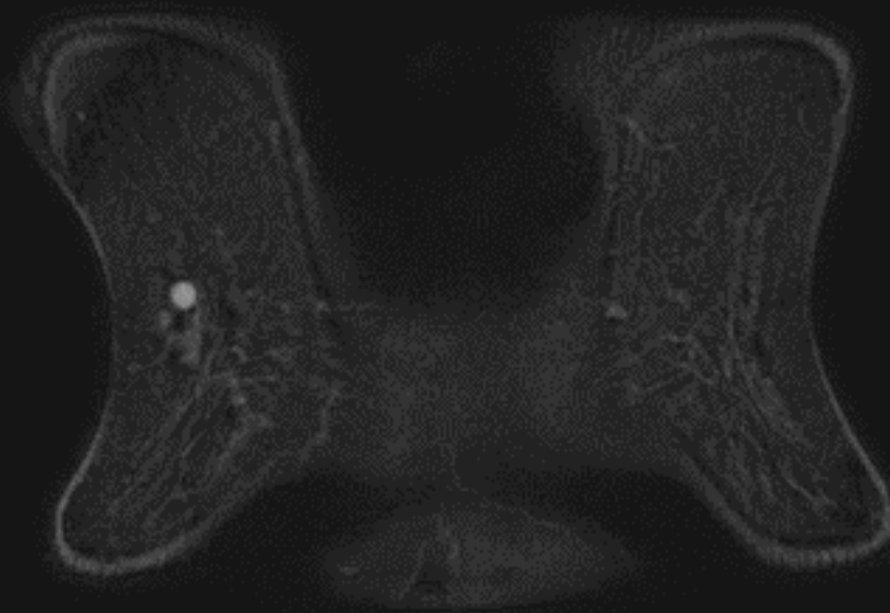
脂肪抑制されたT1WI（造影前）



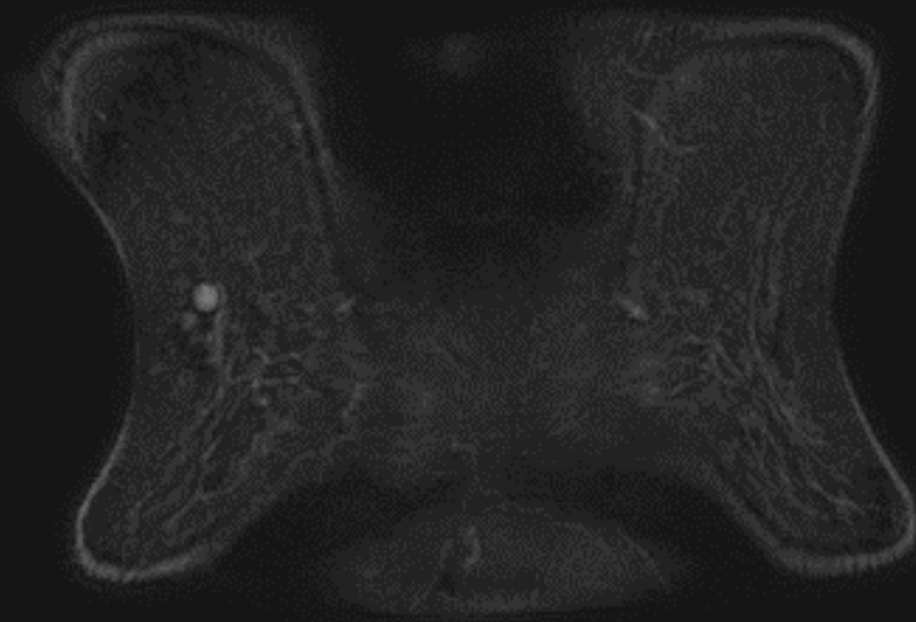
# 脂肪抑制されたT1WI（造影前）



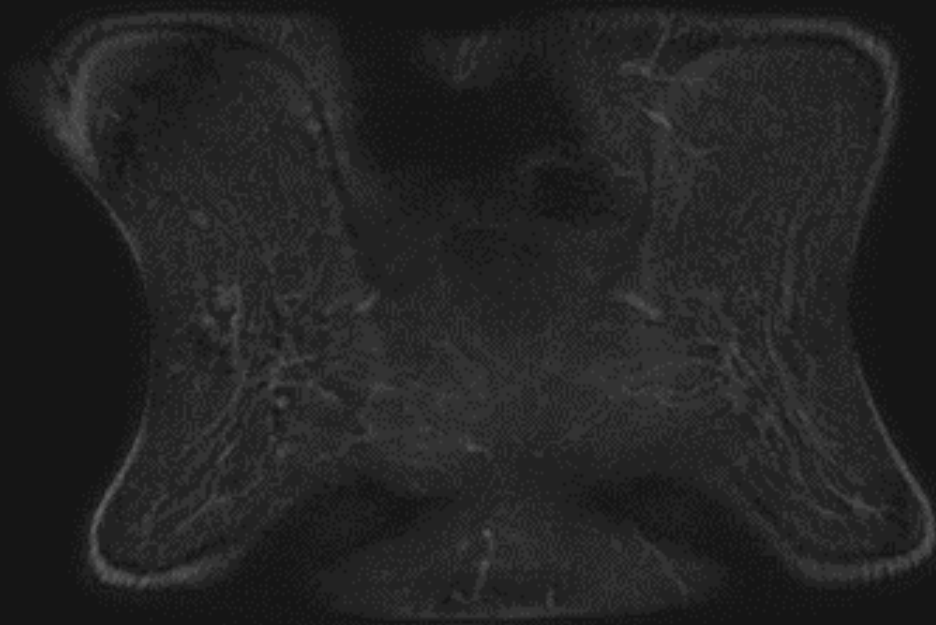
# 脂肪抑制されたT1WI（造影前）



脂肪抑制されたT1WI（造影前）



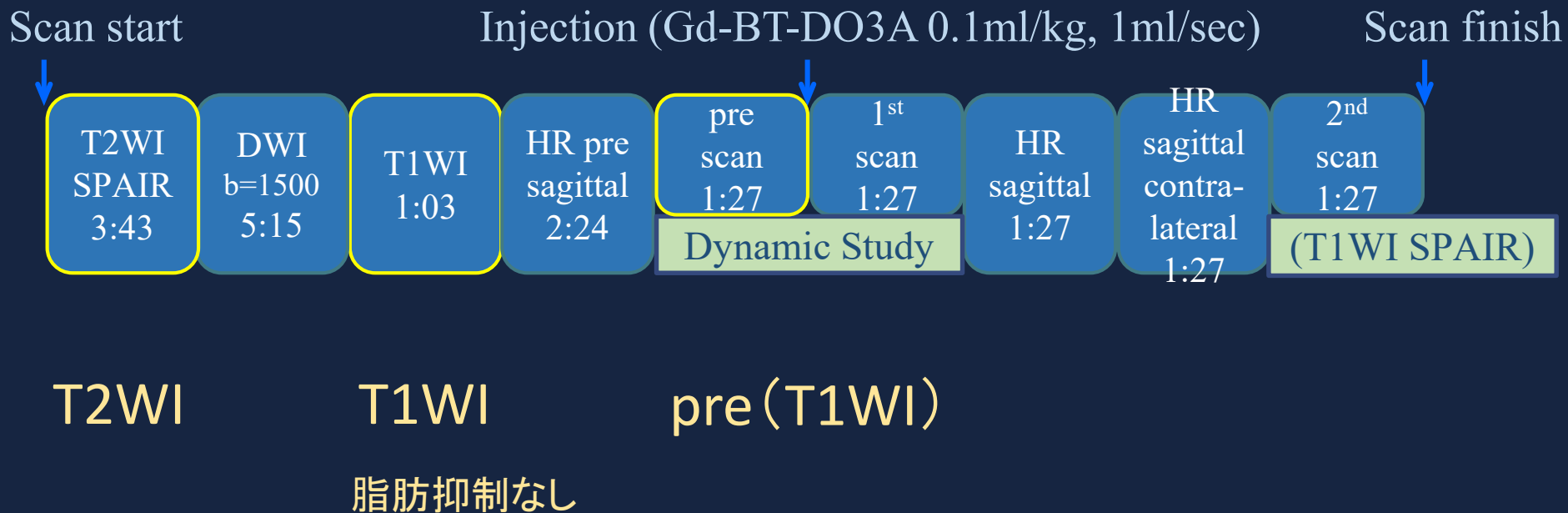
脂肪抑制されたT1WI（造影前）



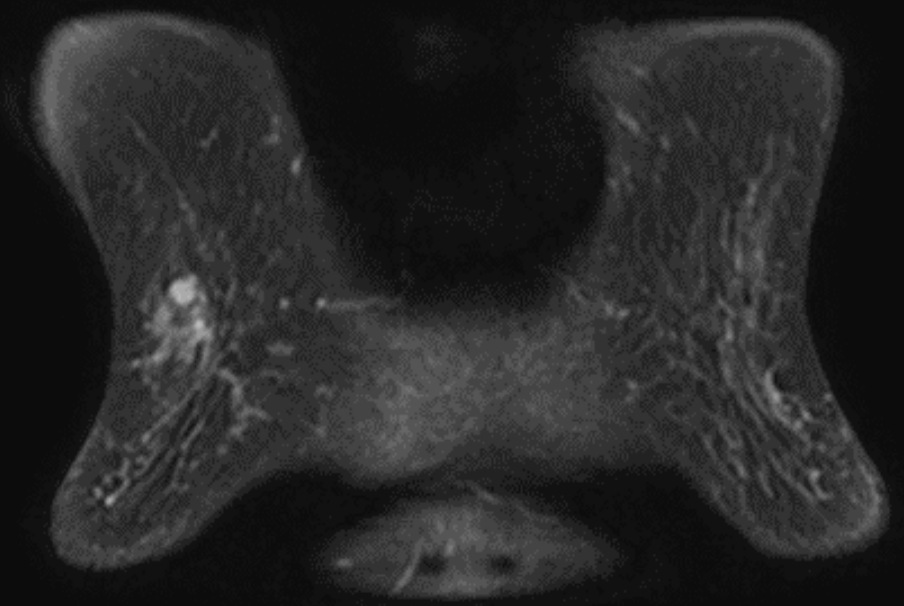


MRI 撮影装置: Ingenia 3T (Philips)

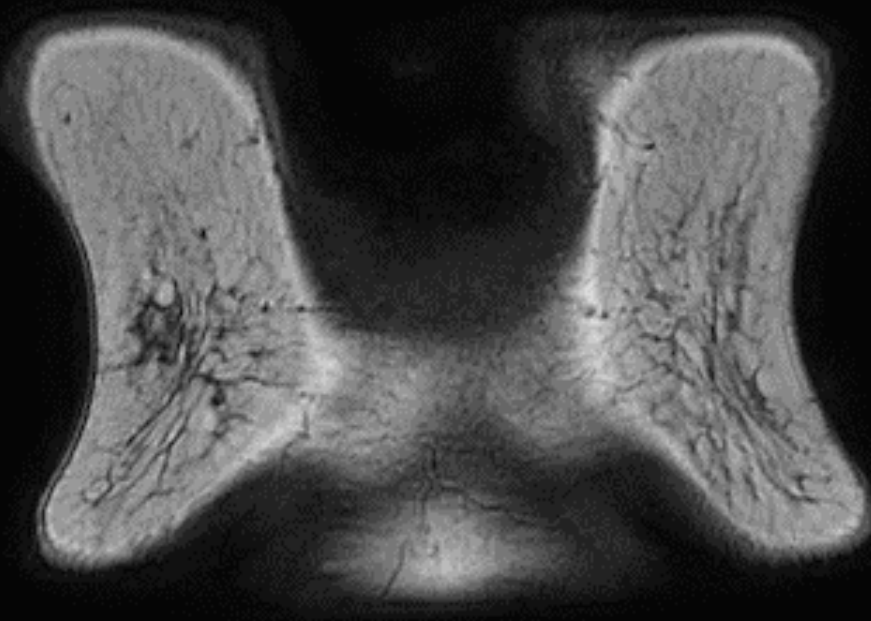
## 撮影プロトコル



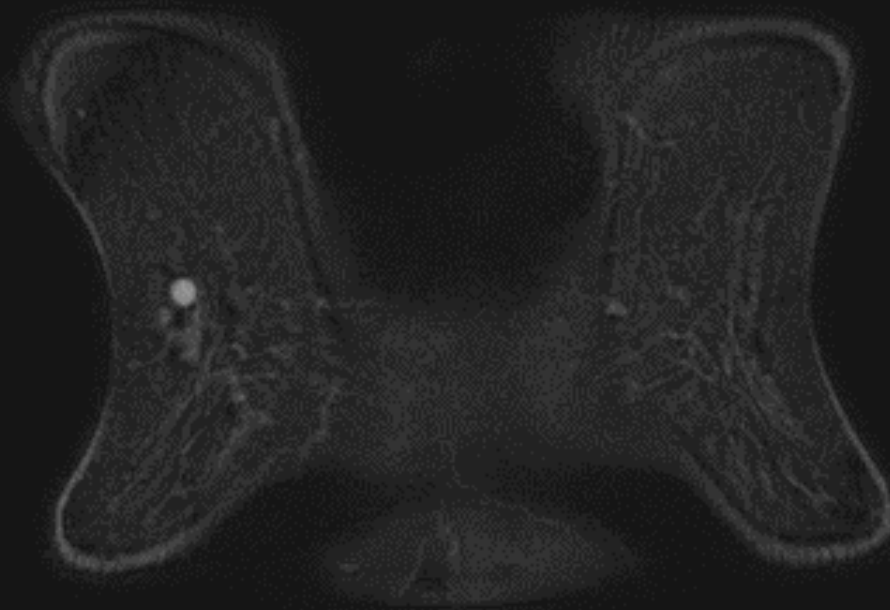
T2WI



T1WI(脂肪抑制なし)

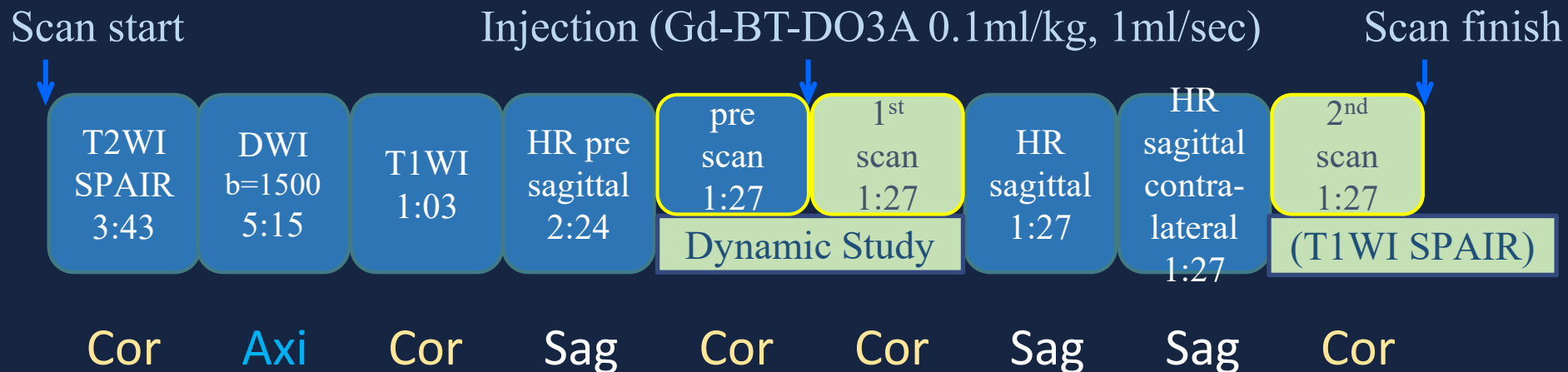


T1WI(脂肪抑制あり)＝造影前



MRI 撮影装置: Ingenia 3T (Philips)

## 撮影プロトコル

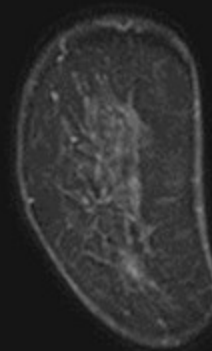
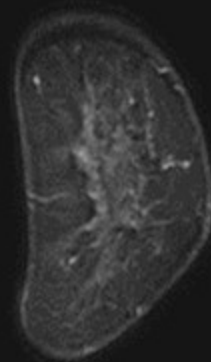
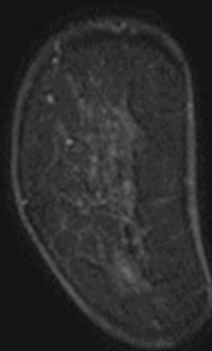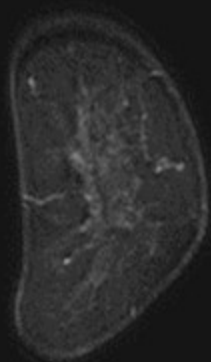


### Dynamic Study (T1WI) 冠状断

造影前はもう呈示したので、早期相・後期相を並べて表示します

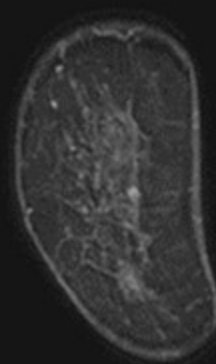
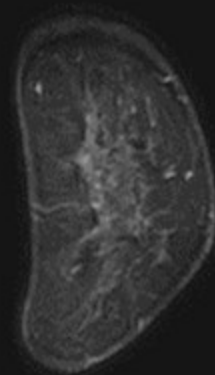
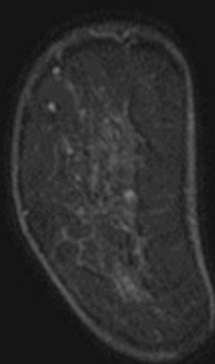
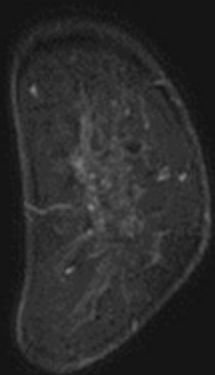Early

Delay



Early

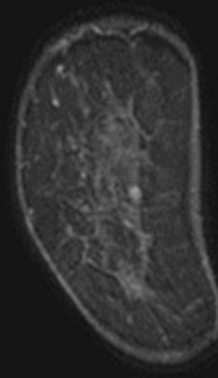
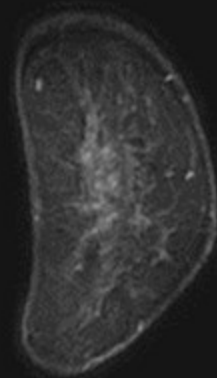
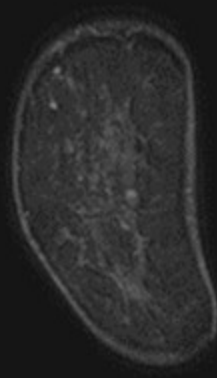
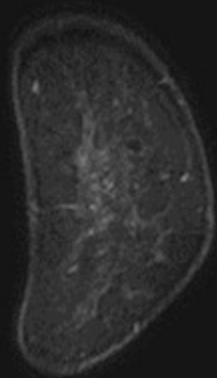
Delay





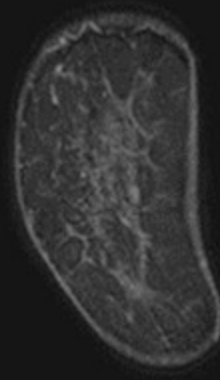
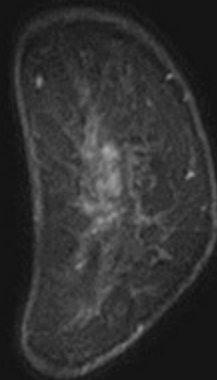
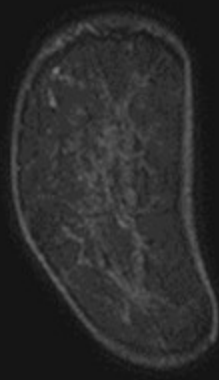
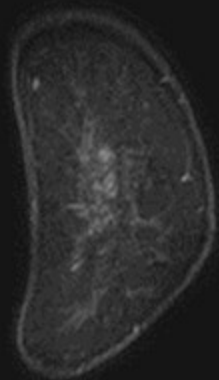
Early

Delay



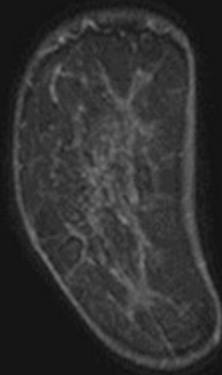
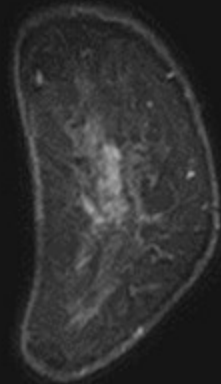
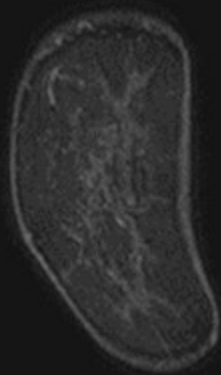
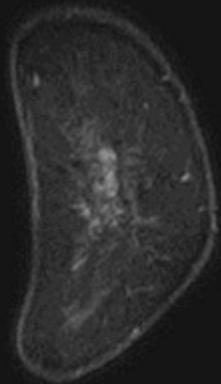
Early

Delay



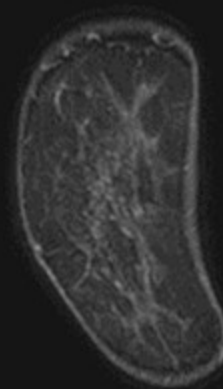
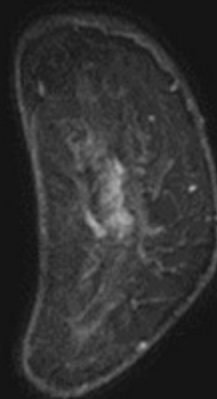
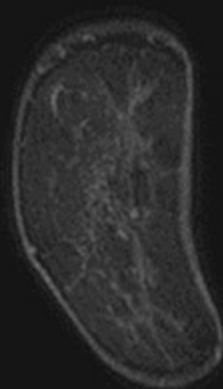
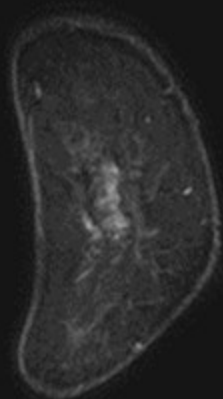
Early

Delay

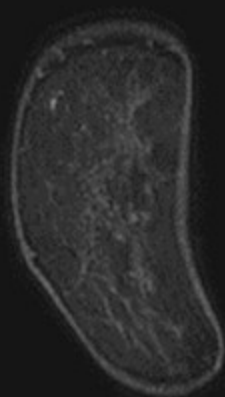
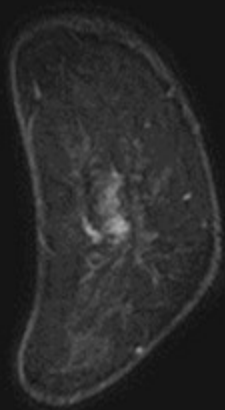


Early

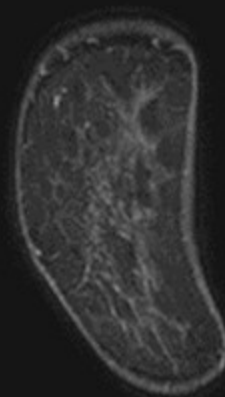
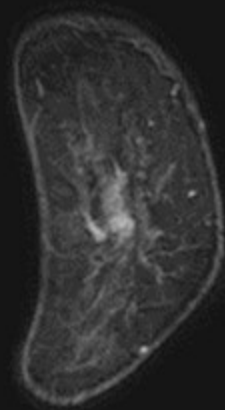
Delay



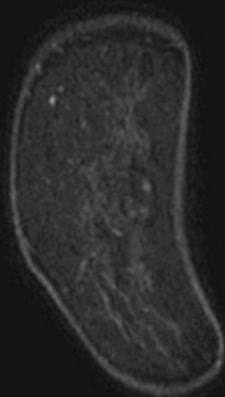
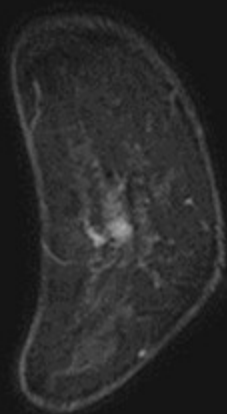
Early



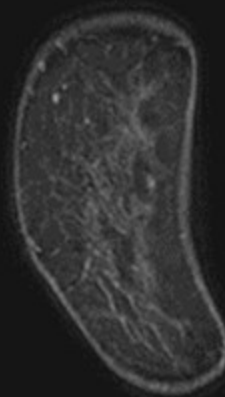
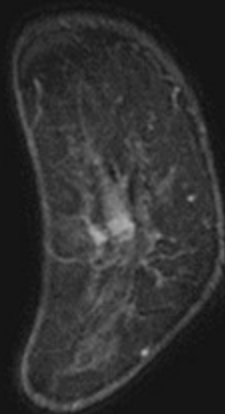
Delay



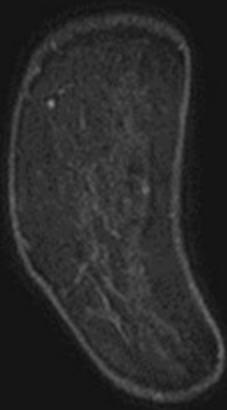
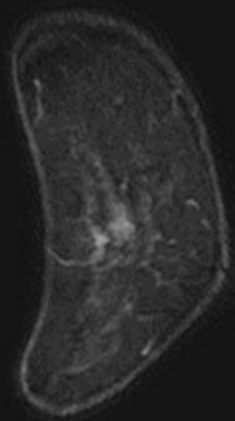
Early



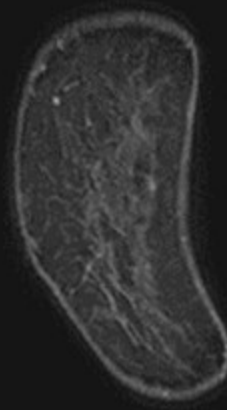
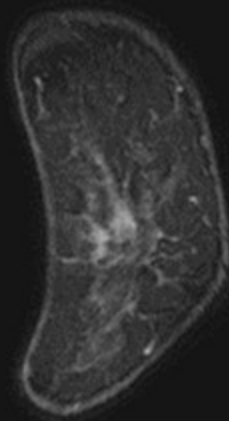
Delay



Early

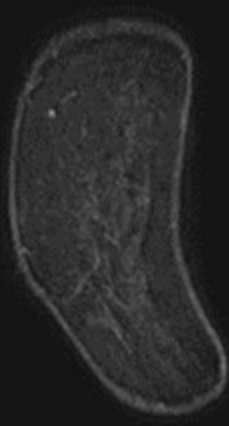
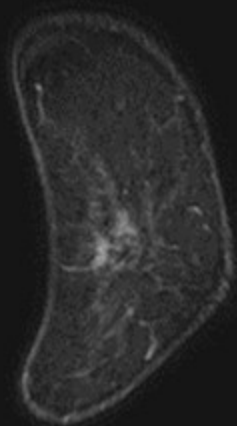


Delay

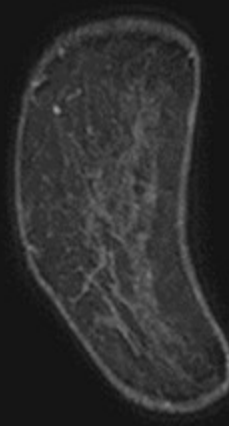
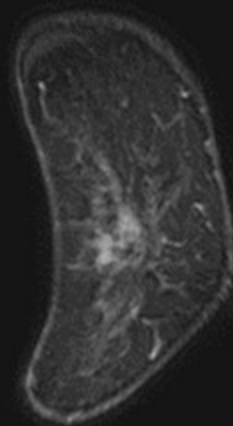




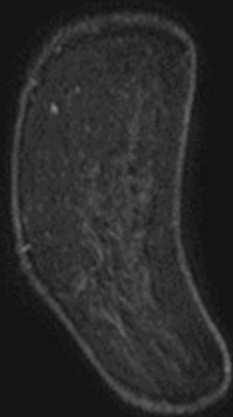
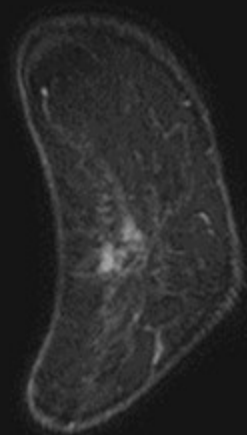
Early



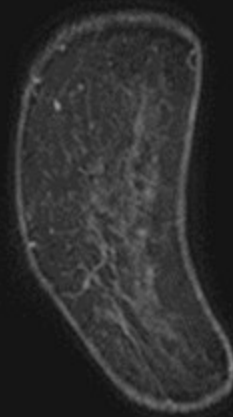
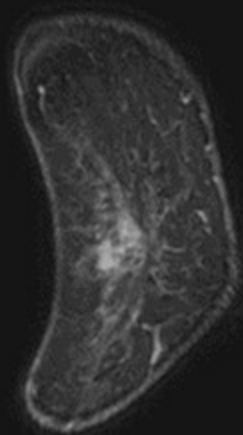
Delay



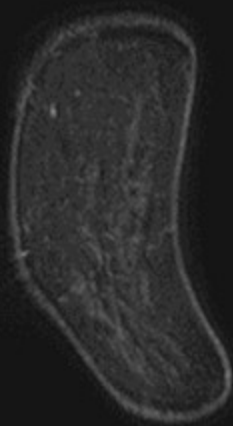
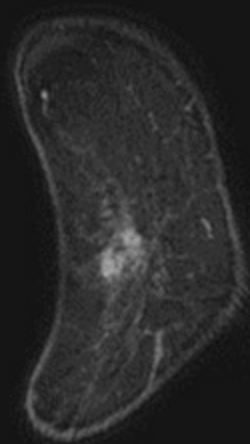
Early



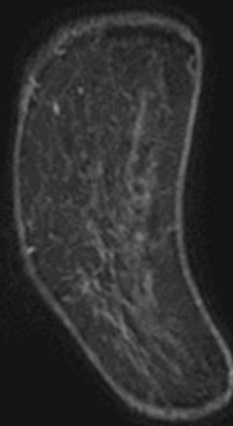
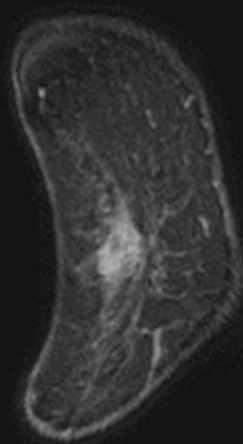
Delay



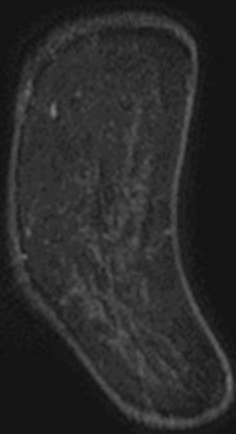
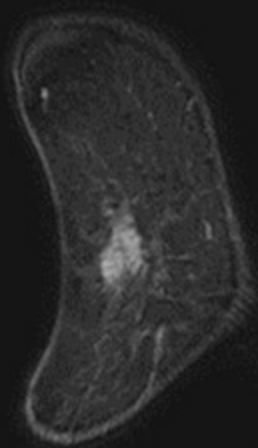
Early



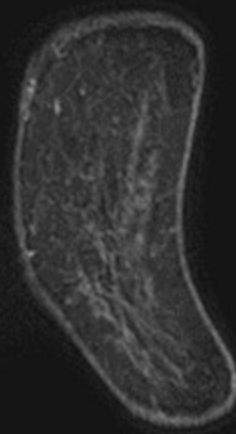
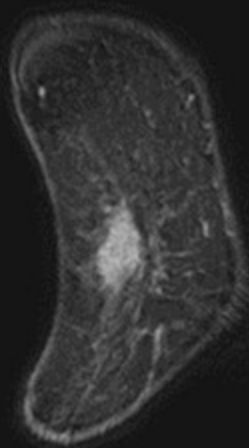
Delay



Early

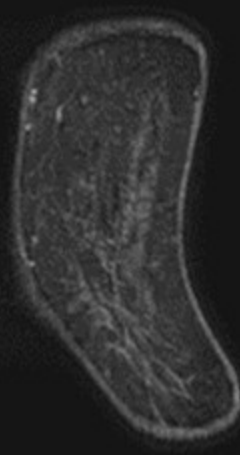
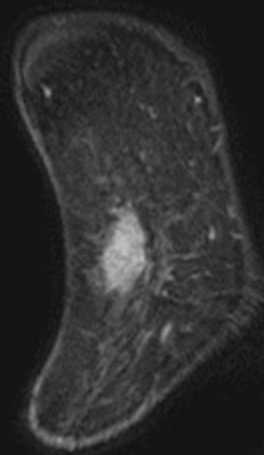
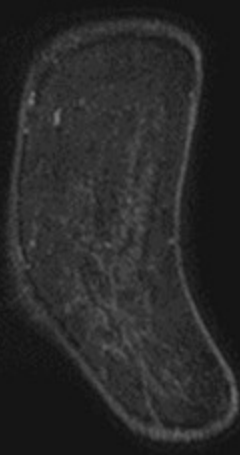
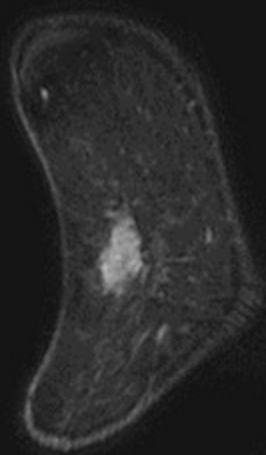


Delay



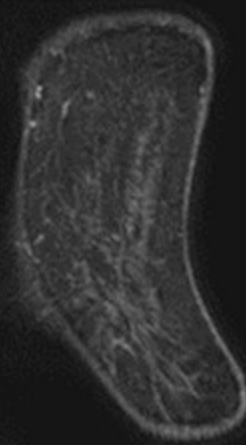
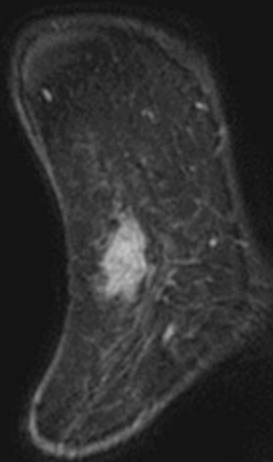
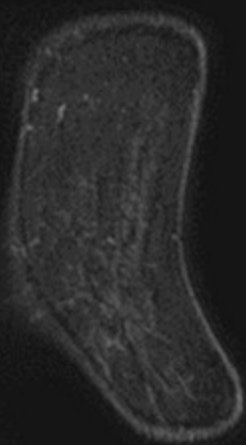
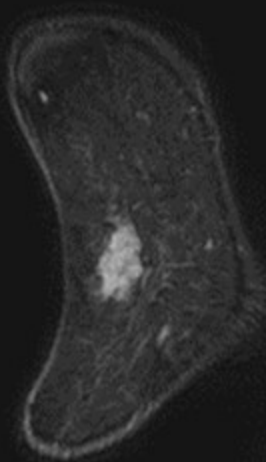
Early

Delay



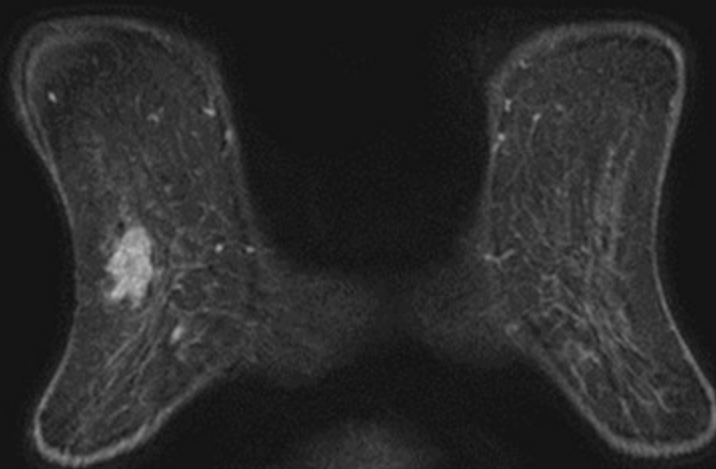
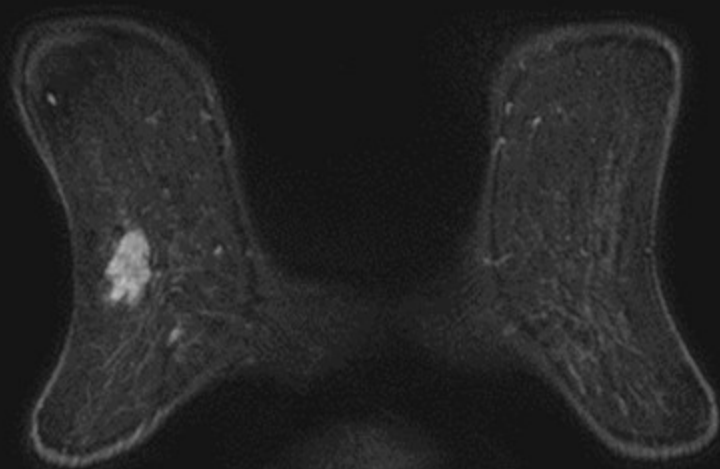
Early

Delay



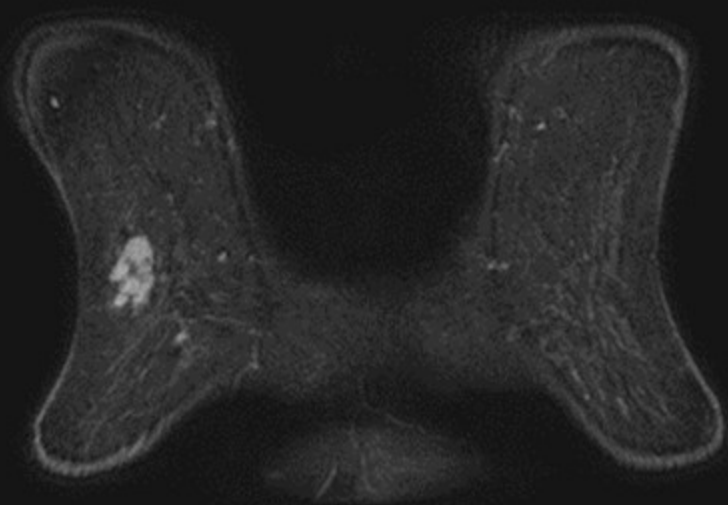
Early

Delay

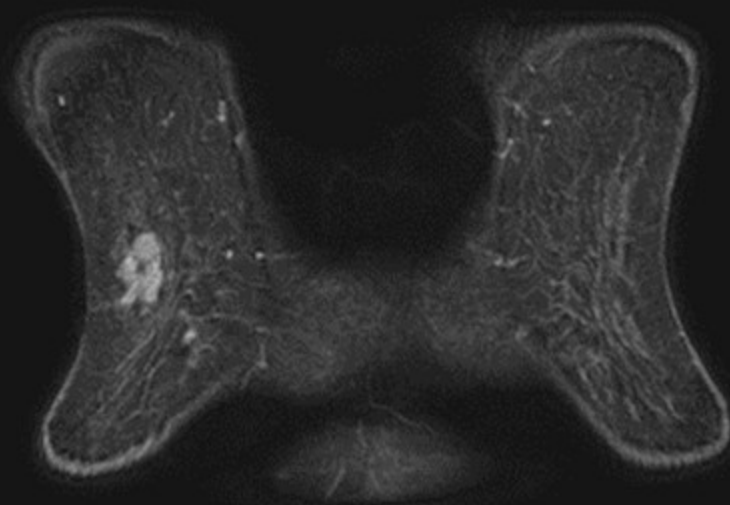




Early

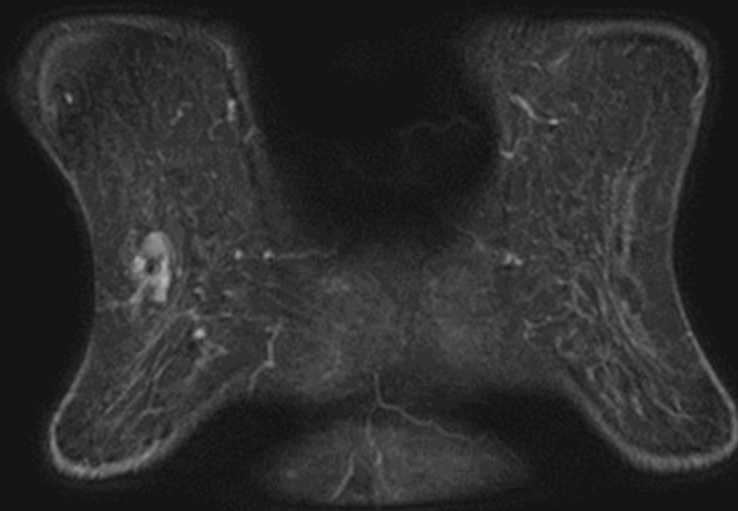
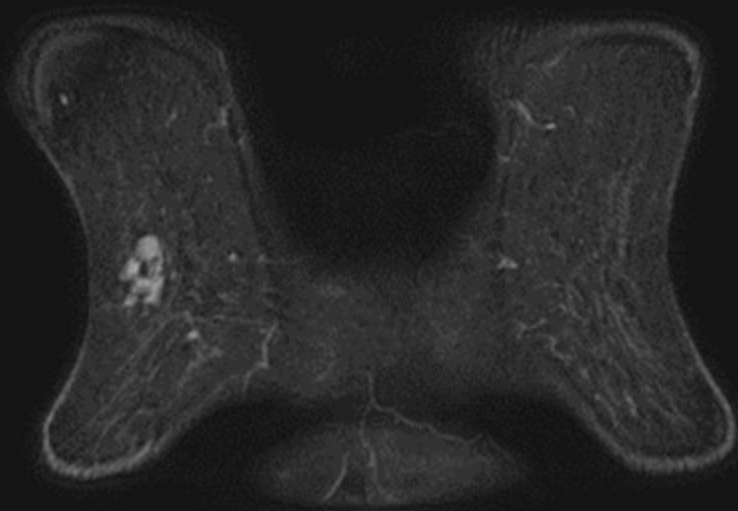


Delay

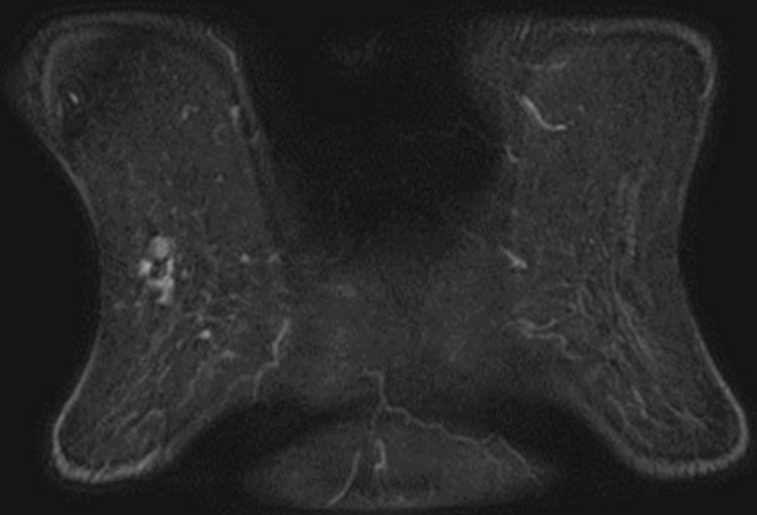


Early

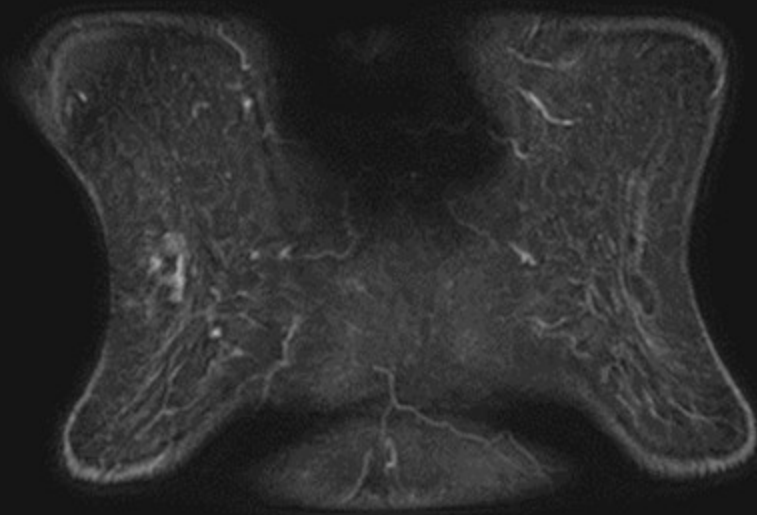
Delay



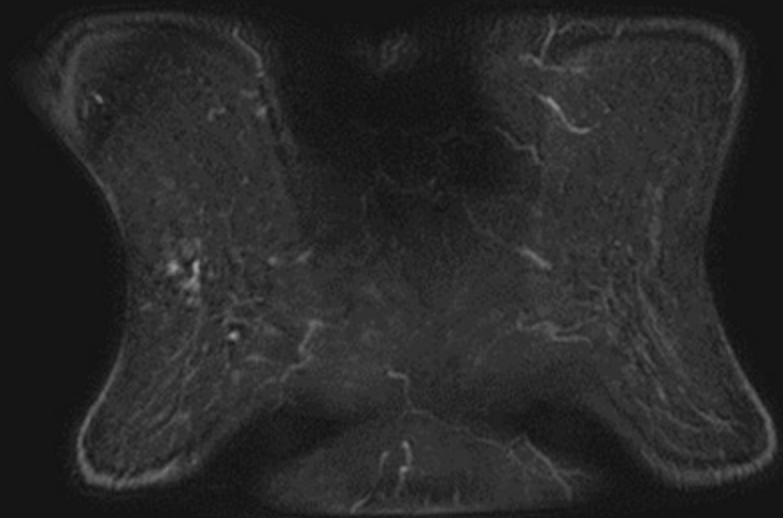
Early



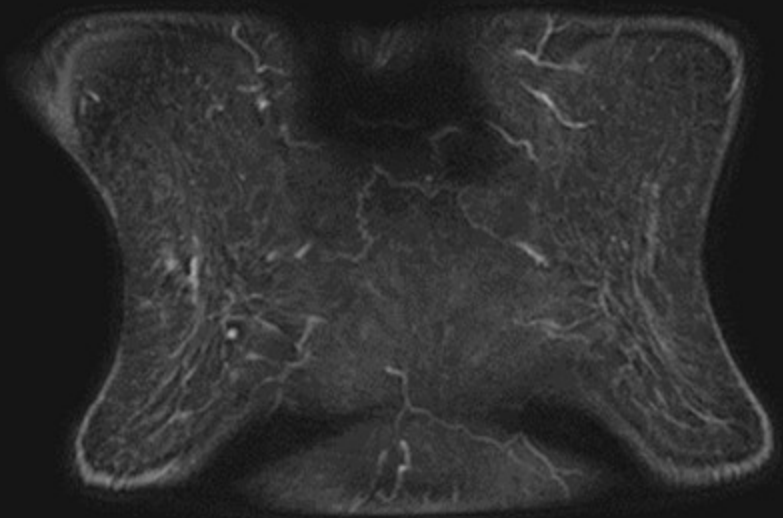
Delay



Early

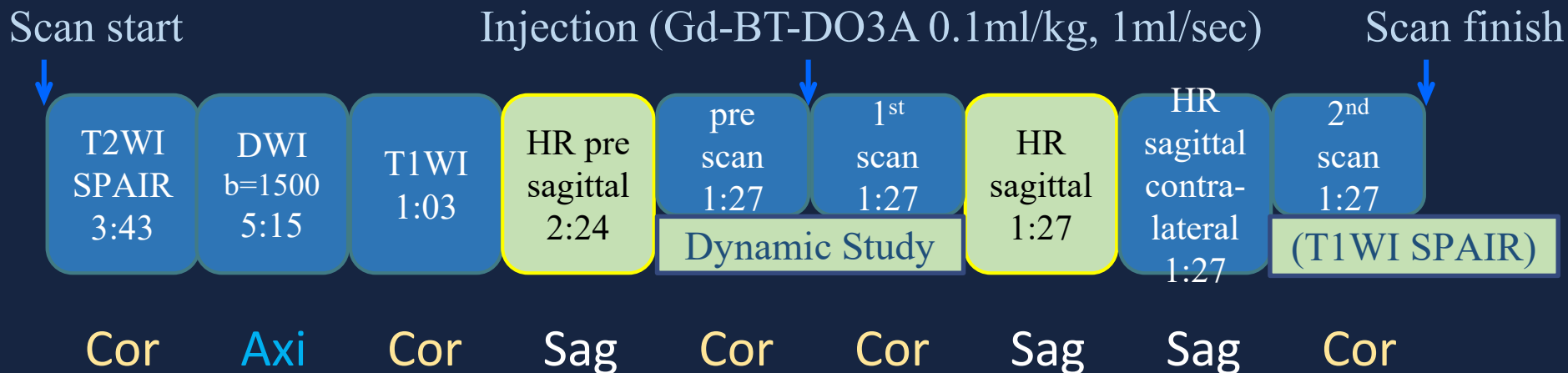


Delay



MRI 撮影装置: Ingenia 3T (Philips)

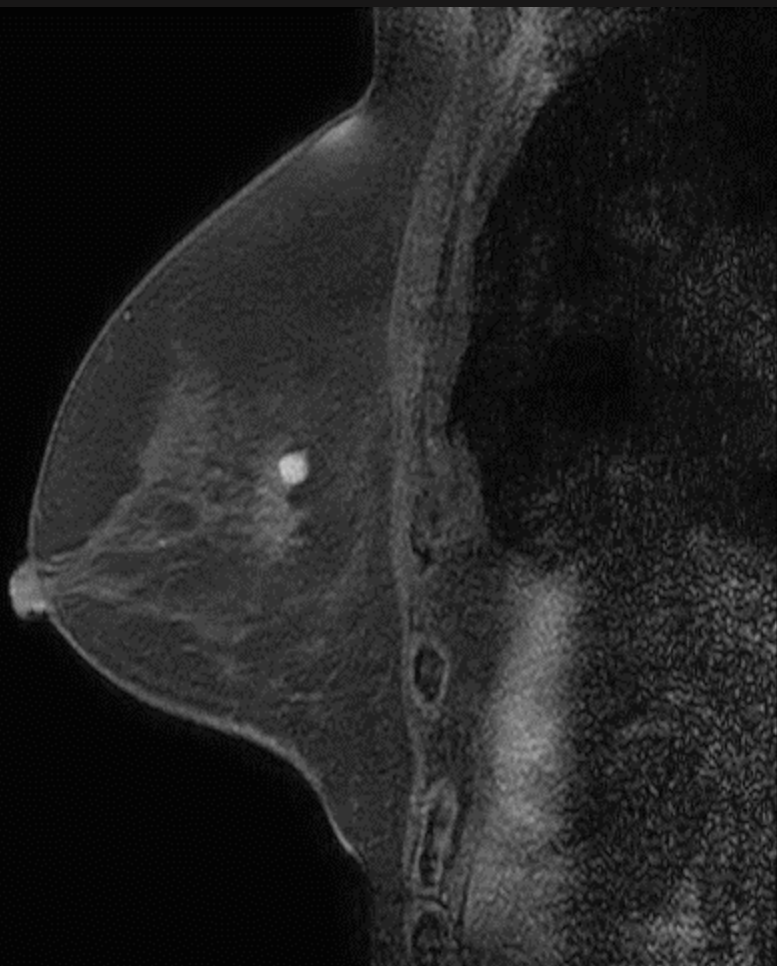
## 撮影プロトコル



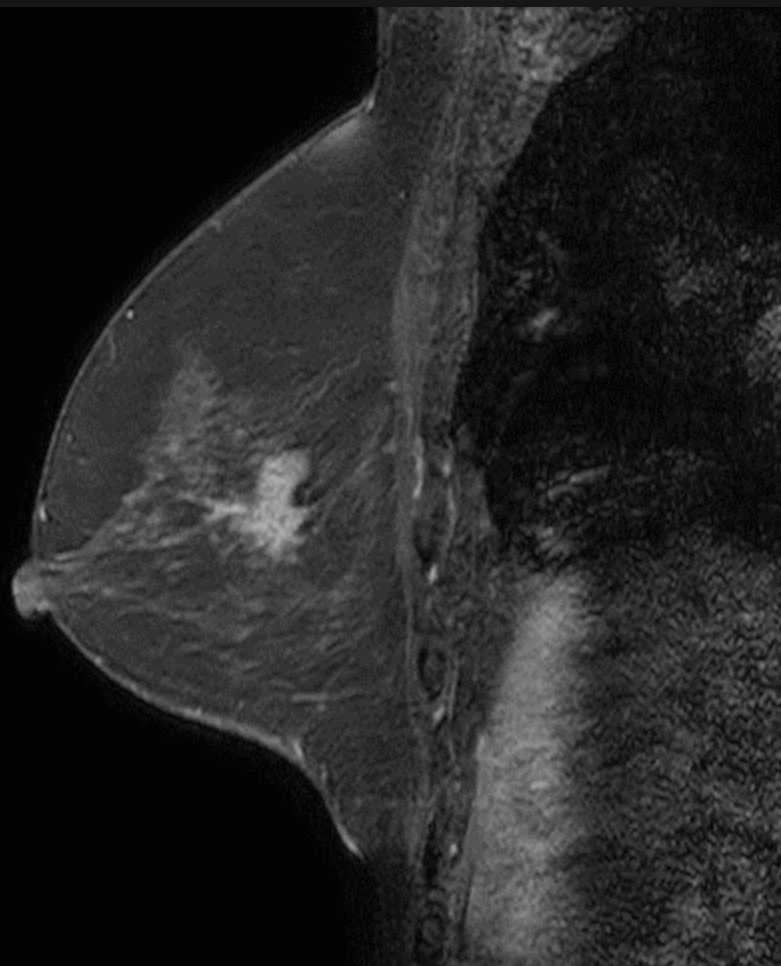
### Dynamic Study (T1WI) の矢状断

プロトコル上、当院の矢状断は、冠状断の早期相よりやや遅れた2~3分ごろに撮られている

脂肪抑制 T1WI

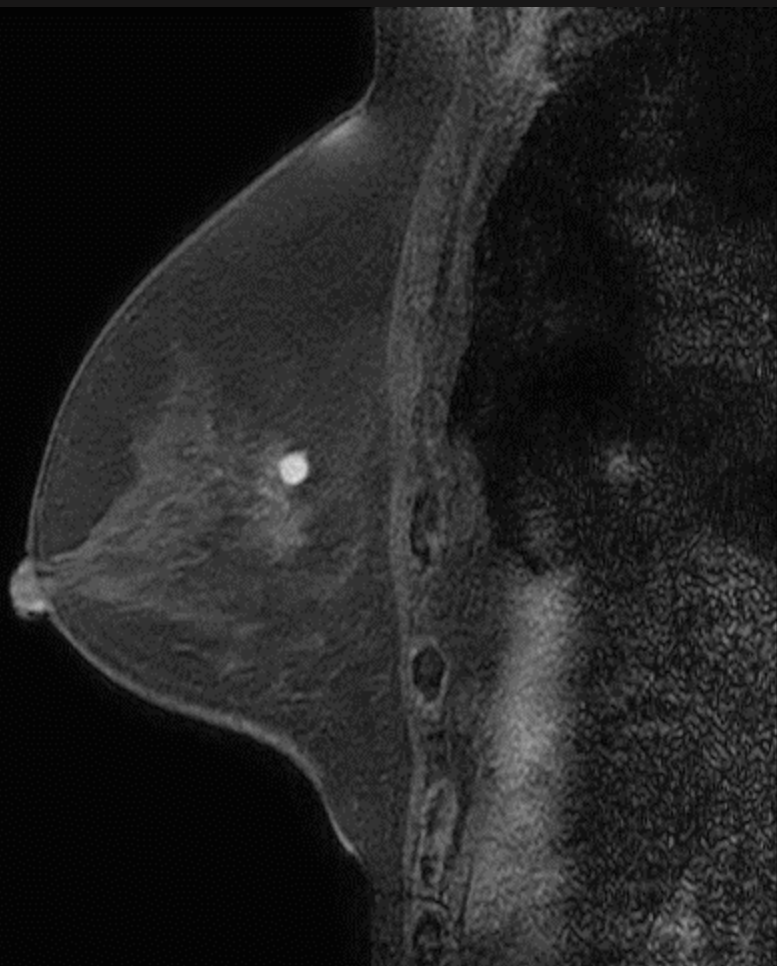


造影前

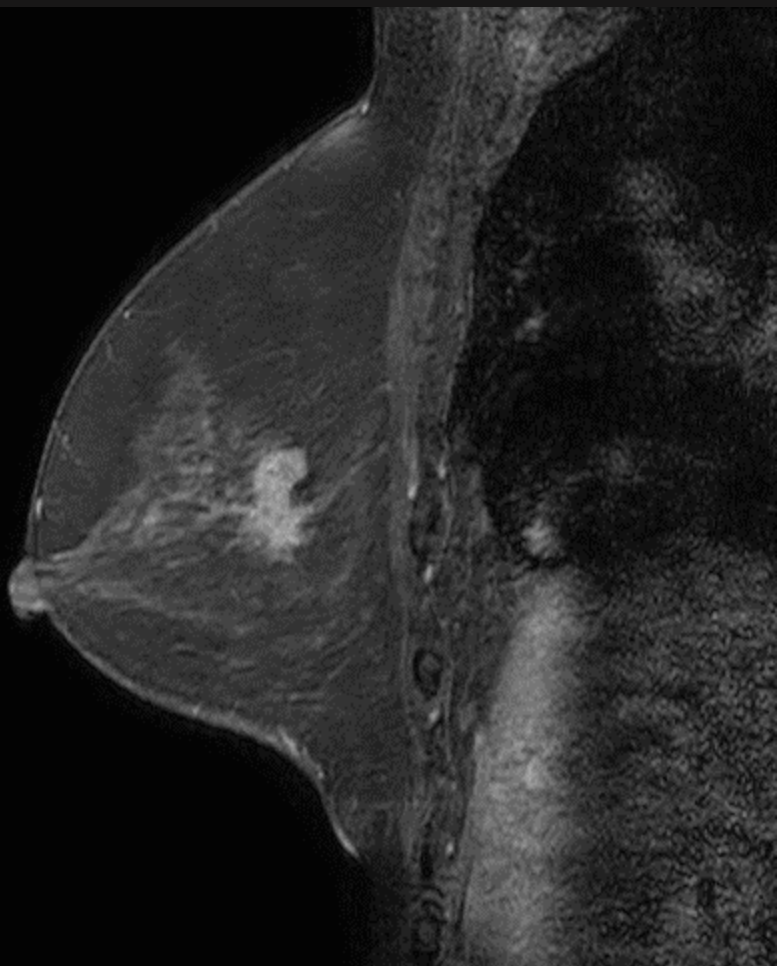


造影後

脂肪抑制 T1WI



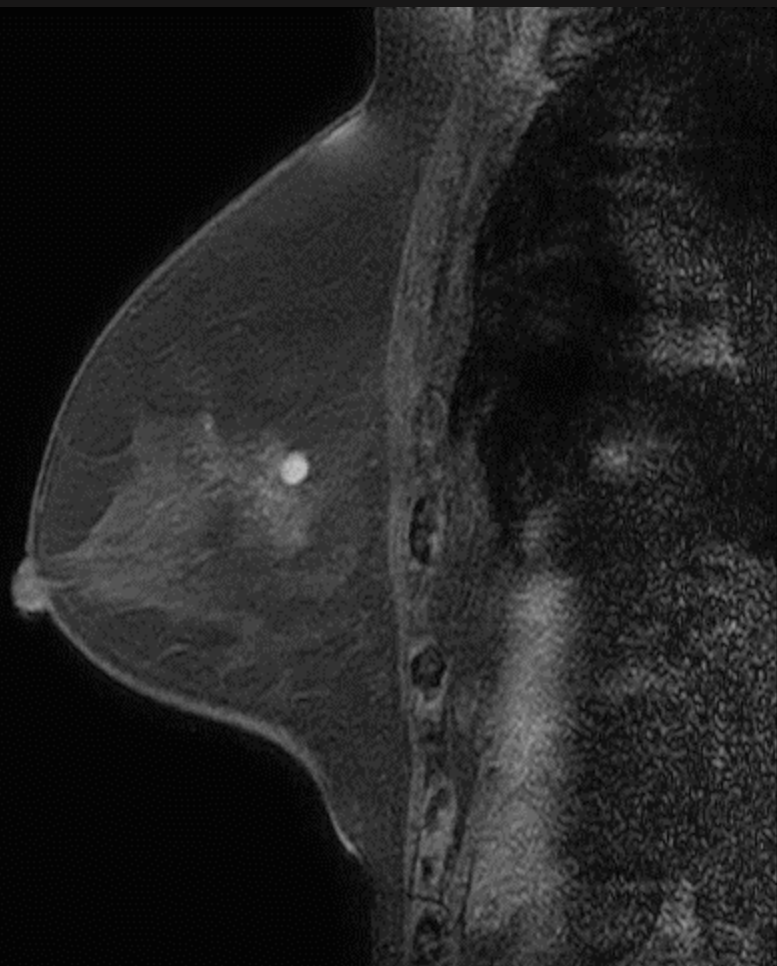
造影前



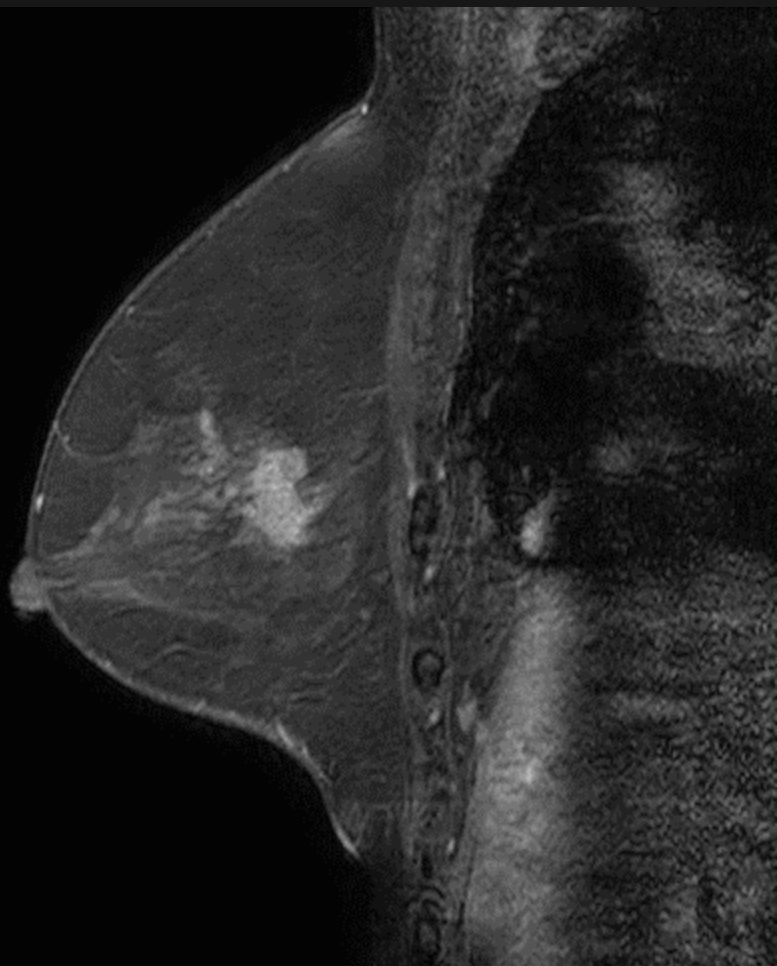
造影後



脂肪抑制 T1WI

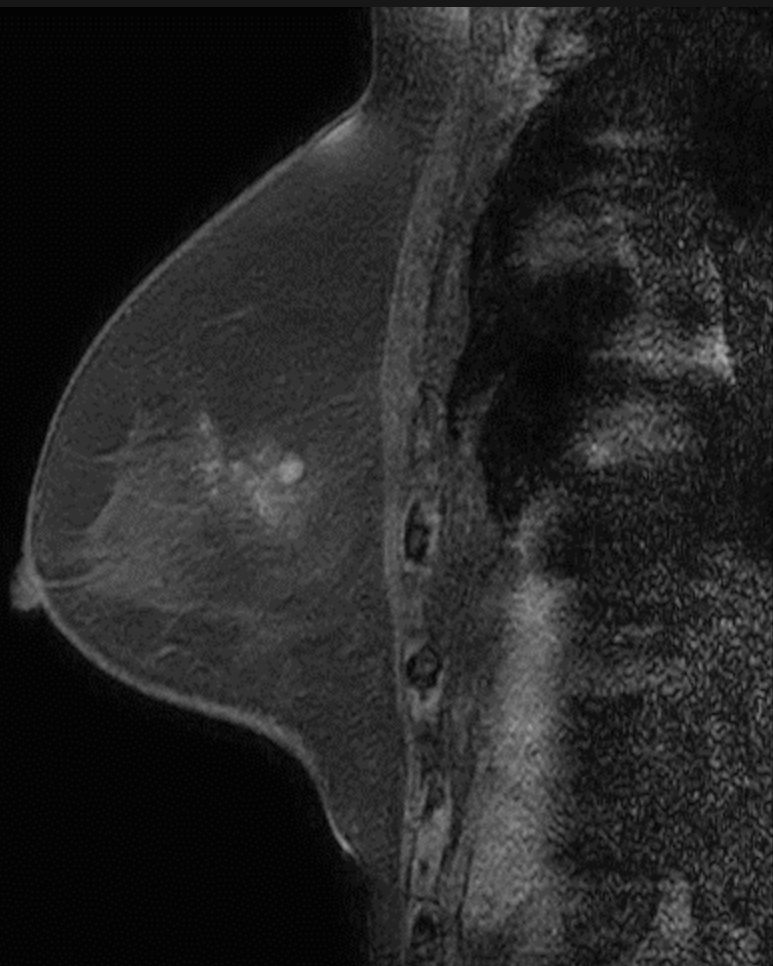


造影前

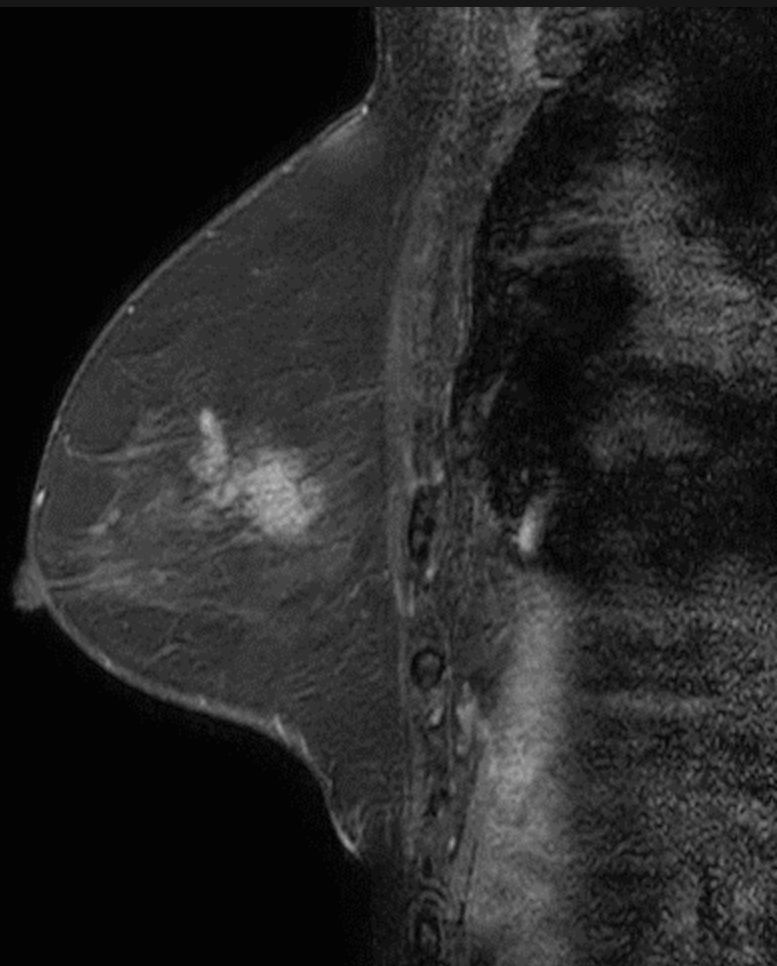


造影後

脂肪抑制 T1WI

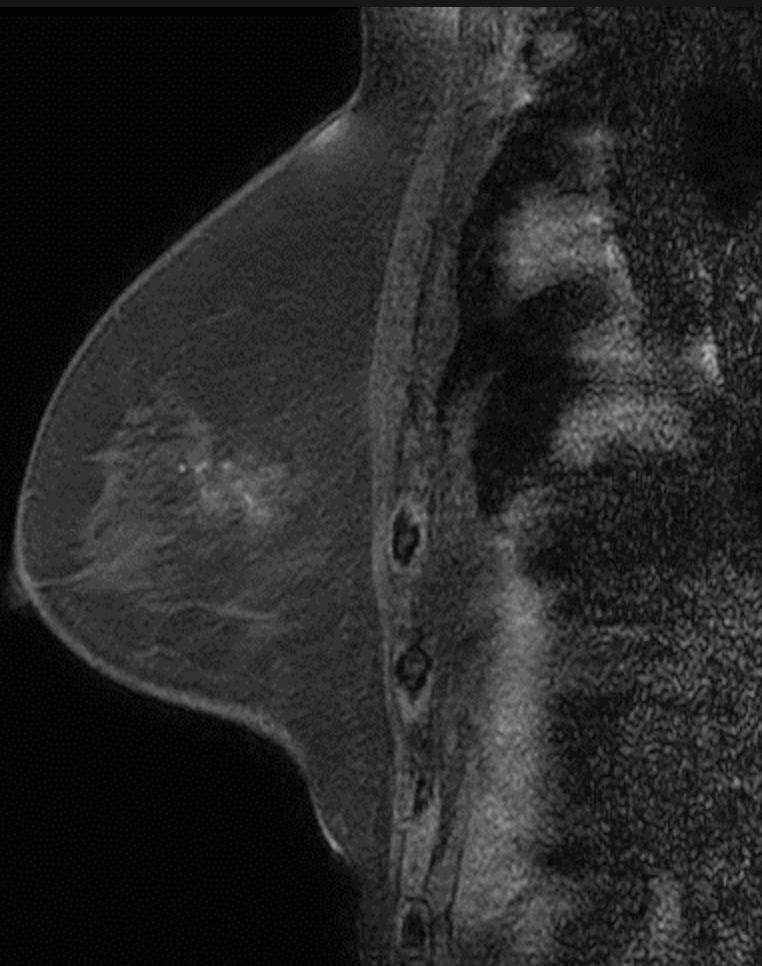


造影前

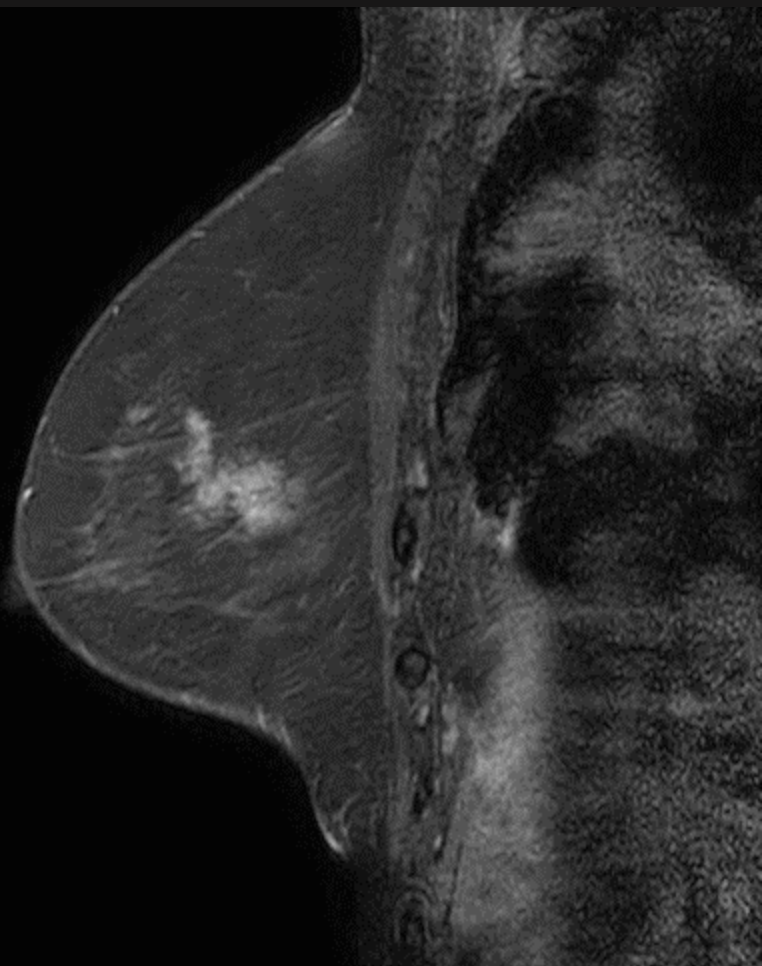


造影後

脂肪抑制 T1WI

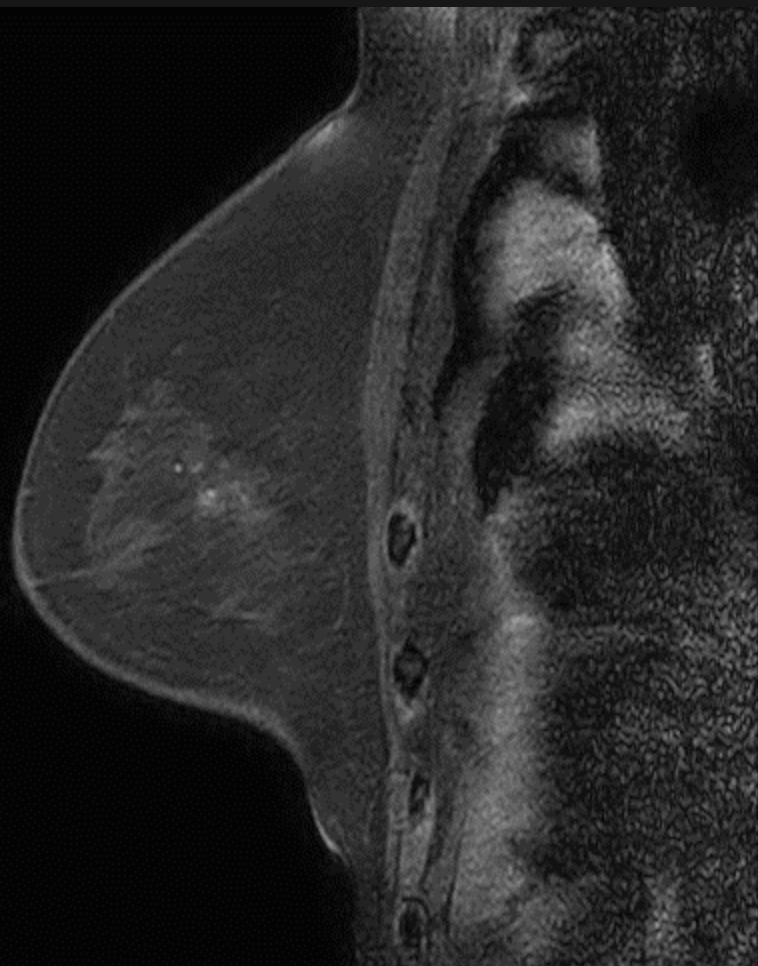


造影前

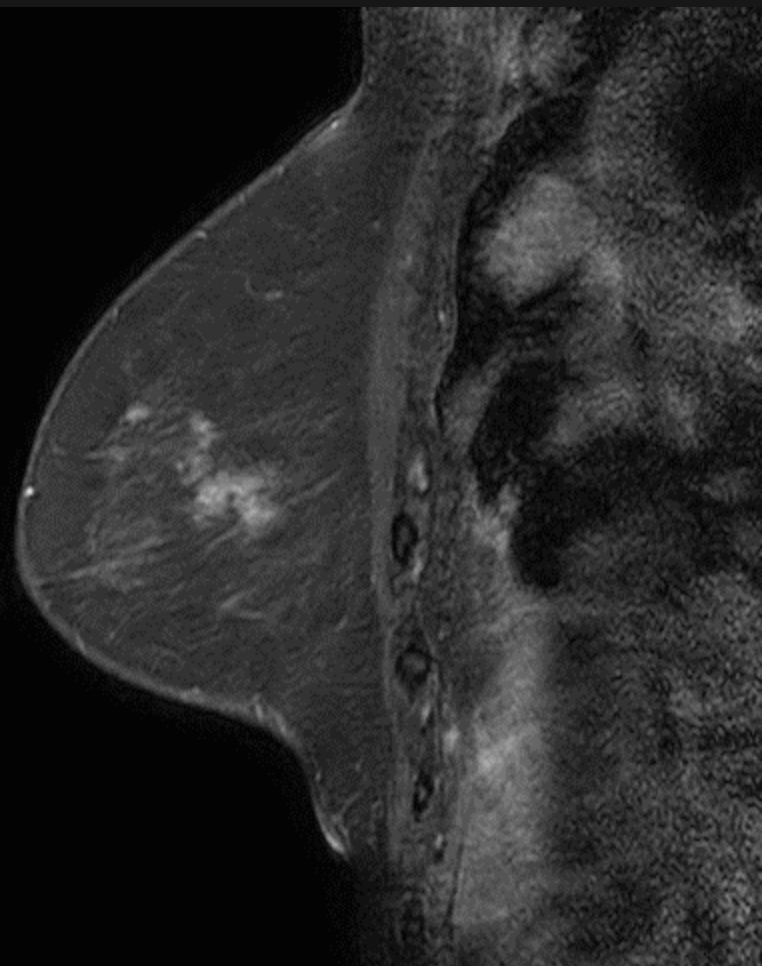


造影後

脂肪抑制 T1WI



造影前



造影後

病理組織所見はセミナー当日に呈示します。